THE HYPOTHALAMUS OF HYRAX SYRIACA WITH SPECIAL REFERENCE TO THE HYPOTHALAMO - HYPOPHYSEAL SYSTEM.

A Thesis Submitted in Partial Fulfillment of the Requirements for the Degree of Master of Science in the American University of Beirut.

By

James S. Jessup

Department of Neural Anatomy
American University of Beirut.
Beirut, Lebanon

1937

The Hypothalamus of Hyrax Syriaca with Special Reference to the Hypothalamo - Hypophyseal System.

Eight Figures.

Contents

The Hypothalamus of Hyrax Syriaca with Special Reference to the Hypothalamo - Hypophyseal System.

Introduction

The coney - Hyriax, or Procavia syriaca, is one of the least studied and at the same time one of the most interesting of the mammals. Its general appearance suggests that it is a rodent but such is not the case. Lyddker and Beddard say that it is an ungulate and base their opinion on the character of the molar teeth, the absence of a clavicle and an acromion, and a reduction in the number of the digits. However, the author found rudimentary clavicles in one out of six specimens that were examined. These clavicles were cartilaginous and showed no signs of ossification. The incisors of the coney, however, are more like those of the rodent in form, but differ in that they continually grow from pulp at their bases. Ibrahim '35, in the study of the thalamic nuclei, suggests that the coney stands in the phylogenetic scale midway between the rodents and the carnicora.

The following research was undertaken for a twofold purpose: first, to study the hypothalamic area of the coney and so add one more link to our knowledge of the nervous system of this animal, and second, to study in detail the complex system of fibers which connects the hypothalamus to the hypophysis cerebri.

Material and Methods

The material used in this investigation was: 1) Two sets

of Pal-Weigert serial sections cut in the transverse plane; 2) Two sets of Methylene blue, and one of Hematoxylin and Eosin serial sections cut in the transverse plane; and 3) two transverse and one saggital serial sections of Silver - pyridine, following Gurdjian's modification of Ranson's method.

There are two main methods in the study of the cellular arrangement with the central nervous system. One is by cell grouping, the method used in this study; while in the other, the divisions are made according to the cell types. Certainly there is much to be said for both. Malone '14, said, "A study of the C. N. S. without taking into consideration the differences of cell character, fails to distinguish between differences of connections, depends merely upon spatial differences and those differences of connections which depend upon differences in cell activities, such cell activities being indicated not only in the nervous system but in all portions of the entire organism, by definite types of cell character". Certainly this is true; but in a region such as the hypothalamus, where many types of cells are found scattered between each other, the cell type of classification becomes very complex. Also, in the study of the hypothalamus of various animals one can see that there is a definite pattern along topographical lines, and that this pattern cannot be constant due to chance but must have some functional significance.

The nomenclature used in this work is based upon the nomenclature that has been used by the group of workers of the Department of Anatomy of the University of Michigan.

The author wishes to express his thanks to Dr. William M. Shanklin under whose supervision this work was done.

Literature

The literature on the mammalian diencephalon in general and the hypothalamus in particular has been extensively reviewed; so no space will be given over to this topic. Those who are interested in such reviews are referred to the works of Ganser 1882, Sachs '09, Greving '23, Minkowski '24, Gurdjian '27, Pines '27, Rioch '29, Krieg '32, Ingram, Hannett, and Ranson '32, and Kappers, Huber and Crosby '36.

Nucleus filiformis (fig. 4.) The term nucleus filiformis was used by Winkler and Potter '11 and '14, Gurdjian '27, Rioch '29, Krieg '32, Ingram, Hannett, and Ranson '32, This cell group has been called the nucleus paraventricularis hypothalami by Friedemann '12, Malone '10 and '14, Greving '25, Gagel '28, Pines '27, Warner '29, Grünthal '29; whereas Rothig '11, Tsai '25, Chu, '32, Papez '32 and '34 describe it as the nucleus magnocellularis.

The nucleus filiformis is divided into a nucleus filiformis anterior and a nucleus filiformis principalis by Rioch '29. A better subdivision according to the study of the coney would be a pars medialis, which lies along the periventricular system and is composed of smaller cells, and a pars posterolateralis, composed of larger cells and extending in the shape of a horn that arches over the fornix. The nucleus is roughly triangular in shape with its apex pointing ventrally.

The nucleus filiformis is composed of darkly staining cells which clearly distinguish it from the surrounding areas of pale staining cells. The nucleus filiformis extends from the posterior pole of the nucleus ovoideus, anteriorly to the posterior one-third of the nucleus hypothalamicus anterior, where it is connected to the nucleus hypothalamicus posterior and the dorsal hypothalamic

area by scattered cells. Medially the nucleus is bounded by the periventricular system of fibers, and laterally by the fornix and the anterior hypothalamic nucleus. Dorsally the nucleus hypothalamicus parvocellularis separates it from the pars ventralis of the nucleus reticularis thalami, while ventrally it becomes continuous with the nucleus periventricularis and the nucleus hypothalami anterior.

The cells of the two parts differ slightly.- Those of the pars posterolateralis are slightly larger and more deeply stained than those of the pars medialis. The cells are medium sized and are fusiform to triangular in shape. The nuclei are small, round, and well stained, while the cytoplasm is granular. Scharrer '33 found multi-nucleated cells, often containing red staining inclusions (Van Gieson stain) which together with high vascularily indicate as secretory function to these cells. These inclusions were also found in the nucleus tangentialis.

The nucleus filiformis has many important fiber connections; The cells of the nucleus are multipolar and give off several axones. The axones of these cells have been traced to the nucleus tangentialis and have been called the tractus filiformis-tangentialis. This is the same tract described by Greving '23, as the tractus paraventricularis cinereus, and by Krieg '32 as the tractus hypothalamo-filiformis. Roussy and Mosinger '33 also describe such a tract. The exact termination of this tract is still doubtful. There is ample evidence that many fibers terminate in the nucleus tangentialis. Other fibers appear to pass through the nucleus tangentialis and pass down into the infundibulum. Fischer et al '35 believe that direct fibers pass from the nucleus filiformis down the stalk and terminate in the posterior lobe of the hypophysis. Another set of fibers arises in the nucleus filiformis

and has a dorsal course. The termination of these fibers was not determined, but Krieg '32 believes that they may end in the nucleus reticularis or the nucleus lenticularis and has called these fibers the tractus filiformis lateralis. From the medial aspect of the nucleus filiformis fine fibers can be seen, emerging and entering into the periventricular system of fibers. Fibers are seen entering this nucleus from the lateral aspect. The exact source of these was not determined, but it is known that this nucleus received fibers from the medial forebrain bundle. It may also receive fibers from the nucleus hypothalamicus lateralis and the nucleus tangentialis.

Nucleus hypothalamicus parvocellularis. - (fig. 3 to 5) The term nucleus hypothalamicus parvocellularis was used by Rioch '29, Warner '29, Papez '32 and '34, and by Ingram, Hannett, and Ranson '32. This cell group was included in the substantia grisea by Malone '14, and described as the nucleus hypothalamicus medialis by Winkler and Potter '11 and '14, Fortuyn '12 and Nissl '13; while Chu '32 described a similar cell group under the name nucleus filiformis.

The nucleus hypothalamicus parvocellularis is differentiated from the surrounding area of cells due to the fact that it is composed of small, pale staining cells. The nucleus hypothalamicus parvocellularis is a flattened disk of cells that forms the dorsal boundary of the hypothalamus for part of its anterior extent.

Anteriorly it extends to the junction of the preoptic area and the nucleus hypothalamicus anterior; while posteriorly it extends a little beyond the posterior limit of the nucleus filiformis. It is bounded dorsally by the nucleus reuniens thalami and

the nucleus reticularis thalami more laterally, but ventrally by the nucleus filiformis. Medially it is continuous with the periventricular nucleus; and laterally it is limited by the nucleus reticularis thalami, throughout most of its extent, but also, by the fornix for part of its anterior extent. The cells are very small, round, and faintly stained. The nuclei are small and round and clear.

The fiber connections of the nucleus hypothalamicus parvocellularis, as seen in the material on hand, were very few. Fibers enter this nucleus from a ventral direction, possibly having originated in the nucleus filiformis. A few fibers were traced from this nucleus to the periventricular system.

Nucleus ovoideus.- (figs. 1 to 3) The term nucleus ovoideus has been used by Gurdjian '27, Rioch '29, Ingram, Hannett, and Ranson '32, Papez '32 and '34. It is similar to the cell group described as the nucleus preopticus periventricularis pars suprachiasmaticus of Loo '31 and Chu '32, the nucleus suprachiasmaticus of Spiegel and Zweig '15, Grünthal '29 and Krieg '32, the nucleus Ty of Friedemann '11, the noyau accessoire supraoptique of Foix and Nicolesco '25 and falls within the noyau anterieur ou principals of Cajal '11.

The nucleus ovoideus is differentiated from the surrounding area in that it is composed of an oval group of closely packed cells. It is well defined throughout most of its extent and gets its name from its appearance in transverse sections. It extends from the preoptic area, where it fuses with this region and posteriorly as far as the middle of the nucleus tangentialis. Medially it is bounded by the periventricular system of fibers

and also by the nucleus periventricularis, laterally by the lateral preoptic area more anteriorly and the nucleus supraopticus diffusus more posteriorly. Dorsal to it lies the nucleus hypothalamicus anterior; while ventral to it is the optic chiasma. The cells are small in size, round to fusiform in shape, and palely stained. The nuclei are small, round, and pale. These cells resemble very closely those found in the periventricular system.

The nucleus ovoideus has few fiber connections. Fine fibers are seen entering it from its lateral aspect, and they seem to originate in the medial forebrain bundle. Krieg '32 believes that these are from the stria terminalis and from the septohypothalamic bundle. Gurdjian '27 believes that it is a bed nucleus for the supraoptic commissures. Arising from this nucleus are fibers that run medially and then turn dorsally to blend with the fibers of the periventricular system.

Nucleus tangentialis.- (figs. 2 to 5) The term nucleus tangentialis has been used by Cajal '11, Gurdjian '27, and Rioch '29. Winkler and Potter '11 and '14 and Malone '14 described this cell group under the name of basal optic ganglion; while Friedemann '11, Greving '25, Gagel '28, Spiegel and Zweig '15, Groschel '30, and Papez '32 and '34 describe it as the nucleus supraopticus. It is the same as nucleus 7 of Grünthal '29.

The nucleus tangentialis is one of the most prominent nuclear groups found in the hypothalamus. The cells are larger and more deeply stained than any others in the adjacent area. It overlies the optic tract and, together with the nucleus supraopticus diffusus, almost completely separates the rest of the

hypothalamus from the optic tract. The main mass of the nucleus tangentialis lies dorsal to the optic tract and may be divided into two main groups. One is more medial and in some animals may be almost continuous across the midline, but not in the coney; the second group is laterally placed. No scattered cells similar to those of the nucleus tangentialis were found in the anterior hypothalamic area, as has been described by Rioch '29 in his study of the thalamus of the carnivora.

The nucleus tangentialis extends anteriorly as far as the middle of the nucleus ovoideus and posteriorly as far as the posterior one-third of the nucleus hypothalamicus lateralis. Medial to this cell group are the nucleus supraopticus diffusus and the periventricular system; while laterally is the ansa lenticularis. Dorsally lies the nucleus preopticus lateralis, the nucleus hypothalamicus lateralis, and the nucleus hypothalamicus anterior; while ventral to the nucleus tangentialis is the optic tract and chiasma.

The cells are large, closely packed, and triangular in shape The cytoplasm is finely granular and deeply stained. The nuclei are large, round, and faintly stained. Some cells in this group show special characteristics and are similar to those that are found in the nucleus filiformis.

The nucleus tangentialis has rich and important fiber connections. Upon careful examination of this nucleus it will be seen that three different fiber systems are given off. One set passes ventro-medially, takes a very superficial course, and then enters the infundibulum. This is the tractus tangentio-hypophyseus, described by many authors, among whom are: Kary '24,

Lewy '24, Espino Vergara '24, Greving '25, Pines '26, Stengel '26, Nicolesco and Nicolesco '29, Cushing '30, Roussy and Mosinger '33, and Fisher et al '35. Greving '25 described it as the tractus supraopticus inferior, but Roussy and Mosinger '33 and Fisher et al '35, prefer to call it the tractus supraopticus-hypophyseus. The tractus tangentio-hypophyseus passes through the nucleus hypothalamicus ventrolateralis and the nucleus supraopticus diffusus, most probably receiving fibers from each. A few more fibers appear to be added from the nucleus hypothalamicus periventricularis. The tract descends into the hypophysis through the ventral wall of the infundibulum. The termination of this tract is of some interest. As the tract curves down to enter the infundibulum a few fine fibers are given off and enter the pars tuberalis. The fibers are clearly seen between the epithelial cells of the pars tuberalis. It is interesting to note that Fisher et al '35 could not find any fibers in the pars tuberalis in a series of cats studies by them. A careful examination of the pars tuberalis of the cat, conducted by the author, verifies the conclusions of Fisher et al '35. The absence of fibers in the pars tuberalis of the cat caused Fisher et al '35 to conclude that Roussy and Mosinger '33 were wrong in their statement that fibers are present in the pars tuberalis, as studied by the latter. However, the present investigation clearly shows that there are nerve fibers that originate from the tractus tangentio-hypophyseus in the coney, but not in the cat. The significance of this difference is not known.

Another set of fibers passes dorsally and then turns caudally. Roussy and Mosinger '32 believe that these terminate in the

mesencephalon. The last set of fibers passes in a dorsomedial direction. These fibers pass through the nucleus hypothalamicus lateralis and reach the nucleus filiformis. Roussy and Mosinger '33 were the first to point out this fiber system. The nucleus tangentialis receives two sets of afferent fibers. One set has already been described as the tractus filiformis-tangentialis. The other set enters from a dorsolateral direction and most probably is composed of fibers or collaterals from the medial forebrain bundle.

Nucleus hypothalamicus anterior.- (figs. 3 to 5) This term has been used by Gurdjian '27, Rioch '29, Warner '29, Chu '32, Krieg '32, Ingram, Hannett, and Ranson '32, and Papez '32 and '34. This cell group is included in vorderer Kern des Tuber cinerum T δ by Friedemann '11, in the substantia grisea centralis by Greving '25 and Groschel '30. It is the nucleus 2 and 3 of Grünthal and the nucleus infundibularis medialis of Winkler and Potter '11 and '14.

The nucleus hypothalamicus anterior is composed of two ill defined condensations of cells found in the anterior hypothalamic area. The ventral condensation is the larger and the more prominent of the two. The nucleus hypothalamicus anterior extends anteriorly from the posterior one-third of the nucleus ovoideus and reaches as far posteriorly as the middle of the nucleus hypothalamicus ventrolateralis. It is bounded medially throughout its anterior three-fourths by the periventricular system and throughout the rest of its extent by the nucleus hypothalamicus ventromedialis; while its lateral boundary is formed by the nucleus hypothalamicus lateralis, the nucleus

supraopticus diffusus, and more posteriorly by the nucleus premammillaris. Dorsally, throughout all its extent, there is an undifferentiated area of cells belonging to the anterior hypothalamic area; while ventral to this cell group lies the nucleus supraopticus diffusus, which is replaced by the nucleus hypothalamicus ventrolateralis more posteriorly. The cells are small to medium sized and round to triangular in shape. The nucleus is round and the cytoplasm is finely granular and well stained.

The nucleus hypothalamicus anterior is traversed by a great mass of fibers, the origin and termination of which cannot be determined from the material on hand. The great mass of these fibers passes in a dorsolateral - ventromedial direction, and suggests that they originate in the medial forebrain bundle and the stria terminalis. A few axones of the cells in this nucleus pass in a medial direction and suggest that this nucleus contributes to the periventricular system.

Nucleus hypothalamicus ventromedialis.- (fig. 4.) The term nucleus hypothalamicus ventromedialis has been used by Gurdjian '27, Rioch '29, Chu '32, Krieg '32, Ingram, Hannett, and Ranson '32, and Papez '32 and '34. It is described as the ventral nucleus of the tuber cinereum Tγ by Friedemann '11 as the principal nucleus of the tuber cinereum by Cajal '11, and as nucleus 6 by Grünthal. The nucleus hypothalamicus ventromedialis is included in the nucleus infundibularis medialis by Winkler and Potter '11 and '14, in the substantia grisea of the third ventricle of Malone '14; whereas Greving '25 and Groschel '30, include it in the substantia grisea centralis.

The nucleus hypothalamicus ventromedialis is a round condensation of cells found in the ventromedial portion of the hypothalamus. It is not very distinct and blends gradually into the surrounding area. The nucleus hypothalamicus ventromedialis extends throughout the posterior one-half of the nucleus hypothalamicus anterior. It is bounded medially by the periventricular system and laterally by the nucleus hypothalamicus ventrolateralis. Dorsal to it is the nucleus hypothalamicus anterior, while ventral to it lies the nucleus supraopticus diffusus more laterally and the nucleus periventricularis ventralis more medially. The cells found in the nucleus hypothalamicus ventromedialis are similar to those found in the nucleus hypothalamicus anterior already described.

The nucleus hypothalamicus ventromedialis is traversed by a mass of fibers similar to those found in the nucleus hypothala micus anterior. Definite fibers may be traced from the nucleus hypothalamicus ventromedialis into the periventricular system of fibers. One set of fibers passes ventrally and becomes intermingled with other fibers of the region. Roussy and Mosinger '35 believe that these fibers enter the infundibulum and so reach the hypophysis. Another set of fibers passes dorsally to traverse the nucleus filiformis and reaches the ventral nucleus of the thalamus. Krieg '32 describes possible connections of the nucleus hypothalamicus ventromedialis with the fasciculus hypothalamicus, the descending filet of the ansa lenticularis, and the medial cortico - hypothalamic tract. Gurdjian '27 believes that it is connected to the medial cortico-hypothalamic bundle, the stria terminalis and the medial forebrain bundle.

Nucleus hypothalamicus dorsomedialis.- (fig. 5.) The term nucleus hypothalamicus dorsomedialis has been used by Gurdjian '27, Rioch '29, Warner '29, Chu '32, Ingram, Hannett, and Ranson '32, Krieg '32, Papez '32 and '34. This nuclear mass was included in the substantia grisea of the third ventricle by Malone '14, in the substantia grisea centralis by Greving '25 and Groschel '30, in the dorsal nucleus (t B) of the tuber cinereum by Friedemann '11 and Pines '27, and in the nucleus infundibularis anterior of Winkler and Potter '11 and '14. It is the same as the nucleus 6 a of Grünthal '29.

The nucleus hypothalamicus dorsomedialis is a very ill-defined condensation of cells in the dorsal part of the medial hypothalamic area. It appears anteriorly at the same level at which the nucleus hypothalamicus ventromedialis disappears, and it extends posteriorly as far as the beginning of the nucleus mammillaris medialis. The nucleus hypothalamus dorsomedialis is bounded medially by the periventricular system and laterally by the nucleus hypothalamicus lateralis more ventrally and the zona incerta more dorsally. At its dorsal boundary it blends with the dorsal hypothalamic area, while ventral to this nucleus is the nucleus periformicalis and the formix. The cells are small, round, and have pale very finely granular cytoplasm. The nucleus is small, round, and well stained.

The nucleus hypothalamicus dorsomedialis has many fibers passing through it and these are probably of the same origin and termination as those found in the nucleus hypothalamicus anterior. In the nucleus hypothalamicus ventromedialis the direction of these fibers is dorsomedial - ventrolateral. Fibers are found arising in this nucleus that may be traced to the periventricular system.

Dorsal hypothalamic area.- (fig. 5.) The term dorsal hypothalamic area has been used by Rioch '29 and by Ingram, Hannett, and Ranson '32. This indistinct and undifferentiated area is included in the nucleus hypothalamicus anterior by Gurdjian '27, in the anterior nucleus of the tuber cinereum by Friedemann '11, in the Hohlengraw by Grünthal '29, in the substantia grisea centralis by Greving '25, and Groschel '30, and in the medial hypothalamic nucleus by Winkler and Potter '11 and '14.

The dorsal hypothalamic area is an indistinct area of cells located in the dorsal part of the hypothalamus. Even in most of the more recent papers it has not been recognised as a separate area or cell group. This area together with the nucleus hypothalamicus posterior may be considered to be the posterior continuation of the nucleus filiformis. This area extends from the nucleus filiformis anteriorly to the middle of the nucleus hypothalamicus posterior, where it blends with this nuclear group. Medially it is bounded by the periventricular system and laterally by the nucleus hypothalamicus lateralis and the zona incerta. It forms the dorsal boundary of the hypothalamicus in this region and separates the rest of the hypothalamus from the nucleus reuniens thalami, and ventrally it is continuous with the nucleus hypothalamicus dorsomedialis. The cells are very similar to those found in the nucleus filiformis, except that they are smaller, more elongated, and not so deeply stained.

The dorsal hypothalamic area is not rich in fibers. It receives fibers from a ventrolateral direction and gives off some fibers that pass dorsally. These may be the same as those des-

cribed by Rioch '31 as entering the nucleus ventralis thalami. No other fibers could be traced with any certainty.

Nucleus hypothalamicus posterior.- (figs. 6 to 7) This term has been used by Gurdjian '27, Rioch '29, Warner '29, Chu '32, Ingram, Hannett, and Ranson '32, Krieg '32, Papez '32 and '34. This nuclear mass is the same as the dorsal nucleus of the tuber cinereum (t a) of Friedemann '11. It is included in the caudo-ventral part of the nucleus mammilo-infundibularis by Greving '25, in the nucleus infundibularis posterior of Winkler and Potter '11 and '14, and in the substantia grisea by Malone '14 and Groschel '30.

The nucleus hypothalamicus posterior occupies the posterior part of the medial hypothalamic area. This nuclear group is a condensation of cells and is quite distinct. It is a cylindrical mass whose longitudinal axis is such that the anterior end is more ventral than the posterior end. The nucleus hypothalamicus posterior extends from the middle of the nucleus hypothalamicus lateralis to the middle of the nucleus mammillaris medialis. Medial to it is found the periventricular system, and lateral to it is the nucleus perifornicalis, more posteriorly, the tractus mammillo-thalamicus. Dorsal to it lies the nucleus hypothalamicus dorsomedialis, ventral to it is the nucleus mammillaris medialis.

Most of the cells are small to medium in size and round to fusiform in shape. The cytoplasm is finely granular and faintly stained; while the nucleus is round and well stained. Scattered throughout this nuclear group, but mostly along its ventral boarder are found larger cells triangular to fusiform in shape.

The nucleus hypothalamicus posterior is relatively free of fibers that pass through it. Fibers pass from it in an anterodorsal direction; and, although they cannot be traced to their terminations, they suggest a connection between the nucleus hypothalamicus posterior and the anterior hypothalamic nuclei. Other fibers pass dorsally and medially and seem to enter the periventricular system. A few fibers pass ventrally and become intermingled with other fibers in this region. Fisher et al '35 believe that these fibers pass down into the hypophysis through the dorsal wall of the infundibulum, and call this tract the tractus tuberohypophyseus. These investigators believe that this tract also receives fibers from the nuclei that are found in the region of the third ventricle. However, it must be stated that with the material on hand the termination of these fibers was not determined although the direction of the fibers suggests that Fisher et al are correct. The nucleus hypothalamicus posterior receives fibers from a lateral direction, and according to Gurdjian '27 and Rioch '31, these fibers come from the medial forebrain bundle. Rioch '31 believes that this nucleus is also connected to the nucleus hypothalamicus lateralis, H_1 of Forel and the external medullary lamina.

<u>Nucleus hypothalamicus ventrolateralis.-</u> (figs. 4 to 6.) This term has been used by Rioch'29. This cell group has been described as the nucleus tuberis lateralis by Malone '10 and '14, Morgan '30, Papez '34, and as the nucleus tuberis by Greving '28. It is included in the nucleus tubero-mammillaris by Gagel '28 and the nucleus infundibularis medialis by Winkler and

and Potter '11 and '14. Chu '32 has shown a similar group in one of his drawings but does not have it labeled nor does he describe such a group.

This is a well defined although a loosely packed group of cells occupying the ventrolateral portion of the medial hypothalamic area. The nucleus hypothalamicus ventrolateralis extends from about the meddle of the nucleus tangentialis and extends as far posteriorly as the beginning of the nucleus mammillaris laterallis. It is bounded medially by the nucleus hypothalamicus ventromedialis more anteriorly and the nucleus mammillaris medialis more posteriorly; while lateral to it is the nucleus tangentialis and the nucleus supraopticus diffusus; more posterior it becomes more superficial and is separated from the lateral wall of the hypothalamus only by the fibers of the tractus supraopticus-hypophyseus of Greving '26. Dorsal to it is the nucleus hypothalamicus anterior while more posterior is the nucleus hypothalamicus lateralis. Ventral to it is the nucleus supraopticus diffusus and the tractus supraopticus-hypophyseus. The cells of this cell group are small, round, and poorly stained. The nuclei are small and poorly stained.

The nucleus hypothalamicus ventrolateralis is traversed by many fibers. It is the bed nucleus of the superior supraoptic commissure. The tractus tangentio-hypophyseus passes through its lateral portion, and there is a good deal of evidence from the material on hand that axones of cells in this nucleus join the tractus tangentio-hypophyseus and descend into the hypophysis. Besides the fibers of the superior supraoptic commissure, this nucleus receives fibers from a dorso-

lateral direction. These fibers are most probably from the medial forebrain bundle and the stria terminalis.

Nucleus perifornicalis.- (figs. 3 to 7.) The term nucleus perifornicalis has been used by Gurdjian '27, Rioch '29, Chu '32, Ingram, Hannett, and Ranson '32 and Papez '32 and '34. This cell group is included in the nucleus mammillo-infundibularis by Malone '14, Greving '28, and Morgan '30.

The nucleus perifornicalis is in reality only a condensation of cells about the fornix, as this fiber bundle passes through the hypothalamus. It is found throughout the extent of the hypothalamus through which the fornix passes, until the fornix begins to form the lateral boundary of the nucleus mammillaris medialis.

The cells are similar to the larger cells found in the nucleus hypothalamicus lateralis, except that they are smaller. The cells are small to medium sized and triangular to fusiform in shape. The cytoplasm is moderately stained, whereas the nuclei are well stained.

The nucleus perifornicalis bound the fornix on all sides. Upon close examination of this nuclear mass one finds that the cells are multipolar. Some of the axones turn and enter the fornix, and others turn away from the fornix and enter the surrounding area and are lost.

Nucleus supraopticus diffusus.- (figs. 2 to 5.) The term nucleus supraopticus diffusus has been used by Gurdjian '27, Rioch '29, Chu '32, Ingram, Hannett, and Ranson '32. It may be homalagous to the nucleus suprachiasmaticus of Loo '31 and is in-

cluded with the anterior nucleus of the tuber cinereum by Friedemann '11, and in the lateral hypothalamic nucleus by Spiegel and Zweig '15. A similar cell group is shown but not labeled by Winkler and Potter '11 and '14.

The nucleus supraopticus diffusus is a very ill-defined group of cells that lie scattered among the fibers of the supraoptic commissures. This nucleus, together with the nucleus tangentialis separates the optic tract from the rest of the hypothalamus. The nucleus supraopticus diffusus extends from the middle of the nucleus ovoideus to the beginning of the nucleus mammillaris medialis. Medially it blends with the nuclei of the medial hypothalamic area; laterally it is bounded by the nucleus tangentialis and the optic tract. The nucleus hypothalamicus anterior is dorsal to it, and the optic tract and chiasma are ventral to it. The cells are mostly fusiform in shape and lie along the fiber systems that pass through it. The cells are small to medium in size and well stained. The nuclei are round to oval and darkly stained.

The nucleus supraopticus diffusus lies among the fibers of the ventral supraoptic commissure and seems to be the bed nucleus of this fiber tract. The axones of certain cells may be followed in a medial direction. The exact termination of these axones is a matter of some doubt in the material on hand. These axones become intermingled with other fibers in this region. They either pass down into the infundibulum and so add to the nerve tracts that pass into the posterior lobe of the hypophysis, or they decussate and run along with the rest of the fibers of the ventral supraoptic commissure.

Nucleus hypothalamicus lateralis.- (fig. 1-7.) This term has been used by Winkler and Potter '11 and '14, Gurdjian '27, Rioch '29, Warner '29, Chu '32, Krieg '32, Ingram, Hannett, and Ranson '32, Papez '32 and '34. The larger cells of this cell group were included in the nucleus tubero-mammillaris; while the smaller were included in the nucleus tuberis lateralis and the substantia gresia by Malone '14 and Morgan '30. Friedemann '11, Greving '25, Groschel '30, and Grünthal '29 described a similar cell group under the name nucleus mammillo-infundibularis; but Gagel '28 included it in his nucleus tuberis.

The nucleus hypothalamicus lateralis is one of the largest nuclei that is found in the hypothalamus. It forms the lateral boundary throughout the entire extent of the hypothalamus. It is not a definite cell mass throughout its entire extent, for in some places it is much more compact than in others. This nucleus includes most of the area lateral to the fornix. It extends from the preoptic region where it is continuous with the lateral preoptic area to the posterior limits of the mammillary nuclei, where it passes over into the zona incerta. Medially are found all the nuclei of the medial hypothalamic area; while laterally it is bound by the internal capsule, cerebral peduncle, substantia negia, and the subthalamus. Dorsally is found the zona incerta and field H_1 of Forel; while ventrally is found the nucleus tangentialis, nucleus supraopticus diffusus, optic tract, and the nucleus mammillaris lateralis. The cells are fusiform in shape and medium in size. The cytoplasm is finely granular, and the nuclei are oval and pale. In the ventrolateral portion the cells are much larger, more deeply stained, and triangular in shape.

The nucleus hypothalamicus lateralis lies among the fibers of the medial forebrain bundle. Three main sets of axones may be traced from the cells of the nucleus hypothalamicus lateralis. One set passes in a dorsomedial direction and may be traced as far as the edge of the nucleus filiformis. These fibers may synapse in the nucleus filiformis or only pass through it to reach the periventricular system. Another set of fibers passes medially and slightly ventrally. These fibers may be traced for a short distance and seem to join the periventricular system. The last set of fibers pass in a dorsolateral direction. Their termination could not be determined. Rioch '31 believes that the nucleus hypothalamicus lateralis has connections with the mammillary nuclei, the medial nucleus of the dorsal thalamus, and the fields of Forel. The afferents of the nucleus hypothalamicus lateralis seem to be limited to the medial forebrain bundle.

Nucleus hypothalamicus periventricularis.- (figs. 1 to7) This group of cells has been described by many authors and it has also been subdivided into several parts. It has been divided into an anterior nucleus by Gurdjian '27, Warner '29, Chu '32, and Papez '32 and '34; and a posterior nucleus, which is in turn subdivided into a dorsal and a ventral part of Gurdjian '27, Rioch '29; but Krieg '32 and Sulkowaja '28 call the ventral portion the nucleus arcuatus hypothalami. Gurdjian '27 also describes those cells found within the periventricular system of fibers as the nucleus periventricularis. All these subgroups will be here described as the nucleus hypothalamicus periventricularis.

The nucleus hypothalamicus periventricularis is a condensation of small cells among the fibers of the periventricular system, also, in and near the walls of the third ventricle. This cell group is continuous anteriorly with the periventricular system of the preoptic area, and it extends as far posteriorly as the mammillary bodies. Medially lies the third ventricle; and laterally, the nuclei of the medial hypothalamic area. Dorsally this cell group is continuous with the periventricular system of the thalamus, bounded ventrally by the ventral limit of the hypothalamus and the supraoptic commissures. The nuclei of the two sides are continuous in the region of the supraoptic commissures and also in the region of the supramammillary commissures. In the region of the nucleus hypothalamicus ventrolateralis the nucleus hypothalamicus periventricularis has a well defined ventral expansion that corresponds to the nucleus arcuatus ~~hh~~ hypothalami of Sulkowaja '28 and Krieg '32. This expansion is triangular in outline with its apex pointing dorsally, at which point it is continuous with the rest of the periventricular system. This expansion is the pars ventralis of rodents as described by Gurdjian '27. The cells are small, round, and pale. The darkly stained nuclei are small and round.

The nucleus hypothalamicus periventricularis is the bed nucleus of the periventricular system of fibers. No axones

may be traced from the cells of this nucleus that do not run along with the periventricular fibers, except in the region near the infundibulum, where axones may be traced that pass ventrally and are believed by Fisher et al '35 to enter the infundibulum. The material on hand does not allow a definite statement on the exact termination of these fibers.

Nucleus premammillaris.- (fig. 5) The term nucleus premammillaris has been used by Gurdjian '27, Grünthal '29, Rioch '29, Krieg '32, Chu '32 and Papez '32, and '34. Several of these authors divide it into a dorsal and a ventral part. In this description no such division has been made for the material on hand does not warrant such a division.

The nucleus premammillaris is a small indistinct condensation of well stained cells. It is located at a level just anterior to the nucleus mammillaris medialis and extends as far posteriorly as this nucleus. Medial to the nucleus premammillaris is the nucleus hypothalamicus anterior, and lateral to it are the nucleus hypothalamicus lateralis and the nucleus hypothalamicus ventro-

lateralis. Dorsal to it is the nucleus periforncalis, and ventral to it are the nucleus supraopticus diffusus and the nucleus mammillaris medialis. The cells are fusiform to round in shape, medium sized, with well stained cytoplasm and nuclei.

The nucleus premammillaris is crossed by a mass of fibers, the origin and termination of which could not be determined. There is evidence, however, that it receives fibers from the nucleus mammillaris lateralis.

Nucleus mammillaris medialis.- (figs. 6 to 7.) This term has been used by all investigators. The nucleus mammillaris medialis has been described by Malone '10, '12 and '14, Cajal '11, Friedemann '11, Winkler and Potter '11 and '14, Nissl '12, Edinger and Wallenberg '20, Tsai '25, Gurdjian '27, Greving '28, Warner '29, Chu '32, Krieg '32, Ingram, Hannett, and Ranson '32, and Papez '32 and '34. Some of the above authors subdivide this nucleus group, but such a division, is uncalled for in the material on hand.

The nucleus mammillaris medialis is the largest nucleus of the mammillary bodies. This cell group is distinguished from the other groups in the mammillary bodies due to its cells. These are paler and smaller than those found in other parts of the mammillary bodies. This cell group extends from the middle of the nucleus hypothalamicus ventrolateralis to nucleus interpeduncularis thalami. Medially it is adjacent to its fellow of the opposite side; while laterally it is bounded by the nucleus premammillaris, the nucleus mammillaris lateralis, and the fornix. Dorsally is found the nucleus hypothalamicus anterior which is replaced posteriorly by the nucleus hypothalamicus posterior;

ventrally it is bounded by nucleus supraopticus diffusus, the nucleus mammillaris lateralis, and more posteriorly the nucleus mammillaris medialis becomes superficial.

The cells are small to medium in size, and round to triangular in shape. The cytoplasm is pale and contains fine granules. The nucleus is round, pale, and fairly large.

The mammillary bodies are known to be the terminal station of the fornix and the mammillary peduncle, although the latter also sends fibers to nearly all the other hypothalamic centers. The mammillary bodies give rise to the tractus mammillo-thalamicus and the tractus mammillo-tegmentalis. In addition to the above connections the medial mammillary nucleus gives off fibers that enter the nucleus mammillaris lateralis.

Nucleus mammillaris lateralis.- (figs. 6 to 7.) The term nucleus mammillaris lateralis has been used by Cajal '11, Winkler and Potter '11 and '14, Nissl '14, Tsai '25, Gurdjian '27, Rioch '29, Warner '29, Chu '32, Krieg '32, Ingram, Hannett, and Ranson '32 and Papez '32 and '34. This cell group is included in the nucleus tuberomammillaris by Malone '10, '12, and '14, and Gagel '28. It is the nucleus intercalatus of Greving '25 and Grünthal '29.

The nucleus mammillaris lateralis is a small but well defined part of the mammillary body. It is composed of the largest cells found in this region. It is triangular in shape with its apex pointed medially. It extends from the posterior pole of the nucleus hypothalamicus ventrolateralis to the posterior one-third of the nucleus mammillaris medialis.

Medial to it is the nucleus mammillaris medialis, and laterally is the cerebral peduncle. The nucleus mammillaris medialis also forms part of the dorsal boundary; as also does the nucleus hypothalamicus ventrolateralis. Ventrally it is superficial. The cells are large, triangular and have large nuclei. The cytoplasm is pale and contains coarse granules.

The main connections of the nucleus mammillaris lateralis have already been discussed with the connections of the nucleus mammillaris medialis. In addition there are two sets of fibers, the first passes medially and enters the nucleus mammillaris medialis, and the other passes dorso-medially towards the nucleus premammillaris, fornix and tractus mammillothalamicus.

Nucleus supramammillaris.- (fig. 7.) The term nucleus supramammillaris has been used by Rioch '29, Chu '32, Krieg '32, Ingram, Hannett, and Ranson '32, Papez '32 and '34, and Grünthal '32, This cell group is the same as that described by Gurdjian '27 as the dorsal premammillary nucleus and by Pines '27 as the raphé kern. It was included in the nucleus tuberomammillaris by Malone '10 and '14, nucleus mammillo-infundibularis by Greving '25, and the nucleus infundibularis posterior by Winkler and Potter '11 and '14.

The nucleus supramammillaris is a small triangular group of well stained, medium sized cells. The nuclei are near the midline and the nucleus of one side is continuous with that of the other by means of scattered cells. The nucleus supramammillaris extends throughout the anterior one-third of the nucleus mammillaris medialis. It is bounded medially by the

fellow of the other side and laterally by the nucleus hypothalamicus posterior. Dorsally it is bounded by the third ventricle; while ventrally is the nucleus mammillaris medialis.

The cells are medium sized and fusiform in shape. The cytoplasm has well stained granules, but the nucleus is oval and pale.

The nucleus supramammillaris is the bed nucleus of the supramammillary commissure. No other connections could be found.

Discussion

The hypothalamus among the mammals is very constant in the nuclear masses present and their fiber connections. Tilney '15 in a detailed study of the diencephalic floor pointed out that the shape of the base of the skull varies considerably in different animals. Le Gros Clark '36 states that the changes in the external shape of the hypothalamus has caused some rearrangement in the nuclear pattern within the hypothalamus. The fact that certain nuclei have shifted slightly in position, that there is great confusion in the terminology applied to these nuclei has caused a great deal of difficulty in attempts to homologize these cell groups.

From our study of the hypothalamus of hyrax syriaca very little may be said as to the classification of this mammal in the animal kingdom. A review of the literature on the comparative neurology of the hypothalamus leaves one in some doubt as to the importance in the changes, if any, in the various groups of mammals. Grünthal '30, '31, and '33 states that there is a progressive simplification of the cyto-architecture in the mammalian scale of evolution; however, Le Gros Clark '36 was not

able to confirm these findings. Le Gros Clark '36 shows that the personal variation in the counting and demarking of the various nuclei is sufficiant to upset Grünthal's theory. Papez '34 believes that there is no progressive simplification in the structure of the hypothalamus. The hypothalamus of hyrax syriaca very closely resembles that of the rodents as described by Gurdjian '27 and Krieg '32, and the carnivora as described by Rioch '29 and Ingram, Hannett, and Ranson '32.

A brief comparison of the hypothalamus of hyrax syriaca and other groups of mammals will be of interest. The hypothalamus of the marsupials is a complex structure and, according to Chu '32, closely resembles the hypothalamus of the rodent. The mammillary body of the opossum is more complex than that of the hyrax. The nucleus filformis of hyrax is, however, larger than that of the opossum. No other marked differences were noticed in a comparison of the work of Chu '32 and the present paper.

The hypothalamus of edentates - armadillo - shows one marked difference from all other mammals in that there is a rudimentary vascular organ. The nucleus targentialis of the armadillo, as described by Papez '32, it better developed than that of hyrax syriaca.

The hypothalami of rodents and carnivora are very similar and so will be considered at the same time. The nucleus tangentialis of hyrax syriaca is more condensed, and no similar characteristic cells are found scattered in the anterior hypothalamic area, as have been found by Rioch '29 in the dog. The nucleus hypothalamicus ventromedialis and nucleus hypothalamicus dorsomedialis are both smaller in hyrax syriaca than in rodents and carnivora,

but the mammillary nuclei of hyrax syriaca are larger than those of the rodents and carnivora.

The hypothalamus of the primates is very similar to that of the hyrax syriaca in most aspects; however, the primates' hypothalamus contains a nucleus tuberis lateralis which is not found in other mammals.

From the above considerations one must conclude that our knowledge of the phylogenetic development of the hypothalamus is such that it cannot be used as a criterion for classification. Ibrahim '35 pointed out that the lateral nucleus of the thalamus of hyrax is more highly differentiated than that of the rodent, but not so highly differentiated as that of the carnivora. The ventral nucleus of the thalamus is as well developed in hyrax syriaca as in the carnivora. The differentiation of the geniculate bodies closely resembles that of the dog in most respects. Ibrahim '35 therefore concludes that the hyrax syriaca is nearly as far advanced in the phylogenetic scale as the carnivora.

The hypothalamus in all the mammals is a center of the autonomic nervous system, which system has the same functions in these animals. The hypothalamus is not a center for the reception of the finer and more discriminative sensations, in which there is such a marked advance as one progresses up the phylogenetic scale. The thalamus and cerebral cortex that increase in complexity in the higher mammals do have an influence upon the hypothalamus, but the centers in these new structures are in all probability remnants of structures nearly as old, phylogenetically, as the hypothalamus itself. The hypothalamus is able to carry out its proper functions, within certain limits, even after

the removal of all higher centers. Since the basic functions of all mammals are nearly all the same, it would be reasonable to expect the nerve centers regulating these functions to be similar. This is, in fact, the belief of most of the authorities upon the mammalian hypothalamus. We must therefore conclude that there is little or no phylogenetic development of the hypothalamus from one mammal to another.

The main fiber connections of the hypothalamus are: the fornix, the stria terminalis, the median forebrain bundle, the mammillary peduncle, and the supraoptic commissures. These fiber pathways place the hypothalamus under influences that arise in other parts of the central nervous system. The exact origin and termination of these pathways will not be discussed here, but those who are interested are referred to textbooks on physiology and neural anatomy and also to the detailed works of Gurdjian '27, Krieg '32, and Kappers, Herber, and Creaby '36. The recent work of Frey '37 indicates that there are fibers from the optic tract that enter the hypothalamus. These fibers leave the optic tract at the chiasma as a single bundle and pass dorsally for a short distance This bundle then splits into two parts each of which is distributed to the homolateral nuclei in the region of the optic recess. These nuclei about the optic recess represent in part the anterior hypothalamic area and in part the preoptic area. This hypothalamic root of the optic nerve was studied by Frey '37 by means of Silver, Marchi, and Weigert methods. In hyrax syriaca fibers could be seen leaving the optic chiasma, turning dorsally and entering into the hypothalamus. These fibers could be traced into the fibers of the supraoptic commissures and could not be traced any farther. The hypothalamic root of the optic tract places the hypothalamic

centers under the influence of optic stimuli.

The hypothalamo - hypophyseal system of fibers is well developed. The fibers that compose this fiber system originate, according to our present knowledge, from various nuclei of the hypothalamus; however, the nucleus tangentialis is the main source of these fibers. The nucleus filiformis sends axones to the nucleus tangentialis where most of them terminate; but a few are believed to join the tractus tangentio - hypophyseus and so reach the hypophysis. The tractus tangentio - hypophyseus passes through the nucleus hypothalamicus ventrolateralis, and the nucleus supraopticus diffusus, see description of these nuclei. There is good evidence to believe that these nuclei each add fibers to this tract. This tract descends into the hypophysis through the ventral wall of the infundibulum and is distributed to the pars nervosa, pars intermedia, and pars tuberalis. Another set of fibers descends into the hypophysis and is called the tractus tubero - hypophyseus by Roussy and Mosinger '33. These fibers are axones that are believed to originate in the nucleus hypothalamicus posterior, the nucleus hypothalamicus ventromedialis, and the nucleus hypothalamicus periventricularis. This tract descends into the hypophysis through the dorsal wall of the infundibulum and is distributed to the pars nervosa and the pars intermedia. No fibers from this tract could be traced with certainty into the pars tuberalis. The two tracts, tractus tangentio - hypophyseus and the tractus tubero - hypophyseus, are collectively called the tractus hypothalamo - hypophyseus.

Summary

The hypothalamic nuclei of hyrax syriaca have been studied and show a close resemblance to those of the carnivora.

The fiber connections of the hypothalamic nuclei were described as seen in silver preparations.

The hypothalamo - hypophyseal system of fibers has been discussed in some detail.

Bibliography

Bucy, P. C. 1932. The Hypophysis Cerebri in: The Cytology and Cellular Pathology of the Nervous System. Hoeber, New York, Vol. 2, page 765.

Cajal, R. 1911. Histologie du systeme nerveux. Tome 2, Paris.

Chu, H. N. 1932. Cell masses of the diencephalon of the Opossum.

--------- 1932. The fiber connections of the diencephalon of the Opossum. Monogr. Nat. Res. Inst. Psychol. Peiping, China.

Croll, M. 1928. Nerve fibers in the pituitary of the rabbit. J. Phy. 66: 317.

Crouch, R. L. 1934. The nuclear configuration of the hypothalamus and subthalamus of macacus rhesus. J. Comp. Neur. 56: 431.

Cushing, H. 1930. On neurohypophyseal mechanisms from a clinical standpoint. Lancet 2: 119; 2:175.

Dejerine, J. 1901. Anatomie des centres nerveux, Paris.

Fisher, C. , Ingram, W. R., and Ranson, S. W. 1935. Relation of the hypothalamo - hypophyseal system to diabetes insipidus. Arch. Neur. and Psyciat. 34: 124.

Fisher, C., Ingram, W. R., Hare, W. K., and Ranson, S. W. 1935. The degeneration of the supraoptic - hypophyseal system in diabetes insipidus. Anat. Res. 63. 29.

Foix, C. and Nicolesco, J. 1925. Anatomie cérébrale: les noyaux gris centraux et la region mesencephalo - sous - optique. Paris.

Fortuyn, A. B. D. 1912. Die Ontogenie der Kerne des Zwischenhirns beim Kaninchen, Arch. f. Anat. u. Phy. 1912: 302.

Frey, E. 1937. Vergleichend - anatomische Untersuchungen über die basale optische Wurzel, die Commissura transversa Gudden und über eine Verbindung der Netzhaut mit dem vegetativen Gebiet im Hypothalamus durch eine "dorsale hypothalamische Wurzel" des Nervus opticus bei Amnioten. Schweiz. Arch. f. Neurol. u. Psychiat. B. 29, H. 2 und B. 40 H.2. S.5.

Friedemann, M. 1911. Die Cytoarchitektonik des Zwischenhirns der Cercopitheken mit besonderer Berücksichtigung des Thalamus opticus J. f. Psychol. u. Neurol. 18: 309.

Gagel, O. 1928. Zur Topik und feineren Histologie der vegetativen Kerne des Zwischenhirns. Zeitschr Anat. 87: 558.

Ganser, S. 1882. Vergleichend - anatomische Studien über das Gehirn des Maulwurfs. Morph. Jahrbuch 7:591.

Greving, R. 1923. Zur Anatomie, Physiologie, und Pathologie der vegetativen Zentren im Zwischenhirn. Ergeb. d. Anat. u. Entwickl. 24: 348.

--------- 1925. Beiträge zur Anatomie des Zwischemhirns und seiner Funktionen. Zeitschr. f. d. ges. Neurol. u. Psychiat. 99: 231.

Greving, R. 1925. Beitrag zur Innervation der Hypophyse. Klin. Wchnschr. 4: 2181.

--------- 1926. Beiträge zur Anatomie der Hypophyse und ihrer Funktion. I Eine Faserverbindung zwischen Hypophyse und Zwischenhirnbasis. Deutsche. Ztschr. f. Nervenh. 89: 179.

--------- 1926. Das nervöse Regulationssystem des Hypophysen-hinterlappens. Zeitsch f. d. ges. Neurol u. Psychiat. 104: 466.

--------- 1928. Das Zwischenhirn - Hypophysensystem: Seine Morphologie, Phylogenese und klinische Bedeutung. Klin. Wchnschr. 7: 734.

--------- 1928. Die Zentralen Anteile des vegetativen Nervensystem, in von Möllendorff: Handbuch der mikroskopischen Anat. des Menschen. 4: 917, Berlin.

Groschel, G. 1930. Uber die Cytoarchitektonik und Histologie des Zwischenhirns beim Hunde. Deutsche. Z. f. Nervenheilk. 112: 108.

Grünthal, E. 1929. Der Zellaufbau des Hypothalamus beim Hunde. Zeitschr. f. d. ges. Neurol. u. Psychiat. 120: 157.

--------- 1930. Vergleichend anatomische und entwicklungsgeschichtliche Untersuchungen über die Zentren des Hypothalamus der Säuger und des Menschen. Arch. f. Psychiat. 90: 216.

--------- 1931. Der Zellaufbau im Hypothalamus des Kaninchens und des Macacus Rhesus nebst einigen allgemeinen Bemerkungen über dieses Organ. J. f. Psychiat. u. Neurol. 42: 425.

Gurdjian, E. S. 1927. The diencephalon of the Albino Rat. J. Comp. Neurol. 43: 1.

Ibrahim, M. 1935. The diencephalon of the coney. To be published.

Ingram, W. R., Hannett, F. I., and Ranson, S. W. 1932. The topography of the nuclei of the diencephalon of the cat. J. Comp. Neurol. 55: 333.

Ingvar, S. 1923. On thalamic evolution. Acta Med. Scand. 59: 696.

Kappers, A. C. V., Huber, C., and Crosby, E. 1936. The Comparative anatomy of the nervous system of vertebrates, Macmillan, New York.

Kary, C. 1924. Pathologisch - anatomische und experimentelle Untersuchungen zur Frage des Diabetes insipidus. Virchow's Arch. f. path. Anat. 252:734

Krieg, W. J. S. 1932. The Hypothalamus of the Albino rat. J. Comp. Neur. 55: 19.

Le Gros Clark, W. E., 1936. The topography and homologies of the hypothalamic nuclei in man. J. Anat. 70:203.

Lewy, F. H. 1924. Infundibulare Veränderungen beim Diabetes insipidus und die Beziehungen zwischen Tuber cinereum und Hypophyse. Zentralbl. f. d. ges. Neurol. u. Psychiat. 37: 397.

Loo, Y. T. 1931. The forebrain of the opossum. J. Comp. Neur. 52: 1.

Maiman, R. 1930. Über die Zentren der Hypophysis cerebri. Ztschr. f. d. ges. Neurol. u. Psychiat. 129: 666.

Malone, E. F. 1910. Über die Kerne des menschlichen Diencephalon. Abhandl. der Königl. Akad. der Wissensch. Berlin.

--------- 1912. Observations concerning the comparative anatomy of the diencephalon. Anat. Rec. 6:281.

--------- 1914. The nuclei tuberis lateralis and the so-called ganglion opticum basale. John Hopkins Hosp. Rep. Monogr. No. 6.

Minkowski, M. 1920. Über den Verlauf, die Endigung und die zentrale Representation von gekreuzten und ungekreuzten Sehnervenfasern bei einigen Säugetieren und beim Menschen. Schweiz. Arch. f. Neurol. u. Psychiat. 6: 201, 7: 268.

Mogilnitsksy, B. N. 1928. Zur Frage über den Zusammenhang der Hypophyse mit dem Zwischenhirn. Virchow's Arch. f. path. Anat. 267: 263.

Morgan, L. O. 1930. Cell groups in the tuber cinereum of the dog, with a discussion of their functions. J. Comp. Neurol. 51: 271.

Nicolesco, J. and Nicolesco, M. 1929. Quelque donnèès sur les centres vegetatifs de la region infundibulotuberine de la frontière diencephalo-telencephalique. Rev. Neurol. 2: 289.

Nissl, F. 1913. Die Grosshirnanteile des Kaninchens. Arch. f. Psychiat. 52: 867.

Papez, J. W. 1929. Comparative Neurology, Crowell, New York.

--------- 1932. The thalamic nuclei of the nine-banded armadillo. J. Comp. Neur. 56: 49.

--------- 1934. Thalamic nuclei of pithecus rhesus. Arch. Neural. and Psychiat. 32:27.

Pines, J. L. 1925. Über die Innervation der Hypophysis cerebri. J. f. Psychol. u. Neurol. 32: H. 1/2.

--------- 1926. Über die Innervation des Mittel - und Hinterlappens der Hypophyse. Ztschr. f. d. ges. Neurol. u. Psychiat. 100: 123.

--------- 1927. Zur Cytoarchitektonik des Thalamus opticus beim Halbaffen. J. f. Psychiat. u. Neurol. 33:31.

Rioch, D. McK. 1929. Studies on the diencephalon of carnivora. I. Nuclear configurations of the thalamus, epithalamus, and hypothalamus of the dog and cat. J. Comp. Neur. 49:1.

--------- 1931. III. Certain myelinated fiber connections of the diencephalon of the dog, cat, and aevisa. J. Comp. Neur. 53:319.

Rothig, P. 1909. Riechbahnen, Septum und Thalamus bei Didelphys, marsupiales. Abhandl. d. Senckenb. Naturf. Gesellsch. 31: 1.

--------- 1911. Beiträge zum Studium des Zentralnervensystems der Wirbeltiere. 3. Zur Phylogenese des Hypothalamus. Folia neurobiol. 5: 913.

Roussy, G. and Mosinger, M. 1933. Rapports anatomiques et physiologiques de l'hypothalamus et l'hypophysis. Ann. de Med. 33: 301.

--------- 1935. L'hypothalamus chez l'homme et chez le chien. Rev. Neurol. 63: 1.

Sachs, E. 1909. On the structure and functional relations of the optic thalamus. Brain 32: 95.

Scharrer, E. 1933. Über die Zwischenhirndrüse der Säugetiere. Ges Morph. u. Physical. München 42: 1.

Spiegel, A. E. and Zweig, H. 1915. Zur Cytoarchitektonik des Tuber cinereum. Arb. a. d. Neurol. Inst. Wien Univ. 22: 278.

Stengel, E. 1926. Über den Ursprung der Nervenfasern der Neurohypophyse im Zwischenhirn. Arb. a. d. Neurol. Inst. Wien Univ. 28: 25.

Sulkowaja. 1928. Centers of heat regulation in the organism. Comparative studies in the cellular structure of the hypothalamus in warm and cold blooded animals. Zeitsch. f. d. ges. Neurol. u. Psychiat. 115:273.

Tilney, F. 1915. The morphology of the diencephalic floor. J. Comp. Neurol. 25: 213.

Tsai, C. 1925. The optic tracts and centers of the opossum. J. Comp. Neurol. 39: 173.

Vergare, E. 1924. Contribucion al estudio de las relaciones entre la hipofisis y los centros diencephalicos. Thesis, Univ. Mex.

Warner, F. T. 1929. The hypothalamus of the opossum. J. Nerv. and Ment. Dis. 70: 485.

Winkler, C. and Potter, A. 1911. An anatomical guide to experimental researches on the rabbit's brain. Amsterdam.

--------- 1914. An anatomical guide to experimental researches on the cat's brain. Amsterdam.

Abbreviations

Ant. com. - anterior commissure

cer. ped. - cerebral peduncle

dor. hyp. - dorsal hypothalamic area

f. - fornix

H_1 - field of Forel H_1

H_2 - field of Forel H_2

Inf. - infundibulum

int. cap. - internal capsule

lat. preo. - lateral preoptic area

lat. vent. - lateral ventricle

med. parol. - medial paraolfactory nucleus

med. preo. - medial preoptic area

n. caud. - nucleus caudatus

n. com. intvent. - nucleus commisuralis interventralis

n. fil. - nucleus filiformis

n. hyp. ant. - nucleus hypothalamicus anterior

n. hyp. dors. vent. - nucleus hypothalamicus dorsoventralis

n. hyp. lat. - nucleus hypothalamicus lateralis

n. hyp. parvo. - nucleus hypothalamicus parvocellularis

n. hyp. perif. - nucleus hypothalamicus perifornicalis

n. hyp. periv. - nucleus hypothalamicus periventricularis

n. hyp. post. - nucleus hypothalamicus posterior

n. hyp. vent. lat. - nucleus hypothalamicus ventrolaterälis

n. hyp. vent. med. - nucleus hypothalamicus ventromedialis

n. mam. lat. - nucleus mammillaris lateralis

n. mam. med. - nucleus mammillaris medialis

n. ovoid. - nucleus ovoideus

n. premam. - nucleus premammillaris

n. ret. - nucleus reticularis

n. reu. - nucleus reuiens

n. subthal. - nucleus subthalamicus

n. sup. mam. - nucleus supramammillaris

n. sup-opt. dif. - nucleus supraopticus diffusus

n. vent. vent. med. - nucleus ventralis pars ventromedialis

opt. ch. - optic chiasma

opt. tr. - optic tract

rhinen. - rhinencephalon

sub. nig. - substantia nigra

vent. III - third ventricle

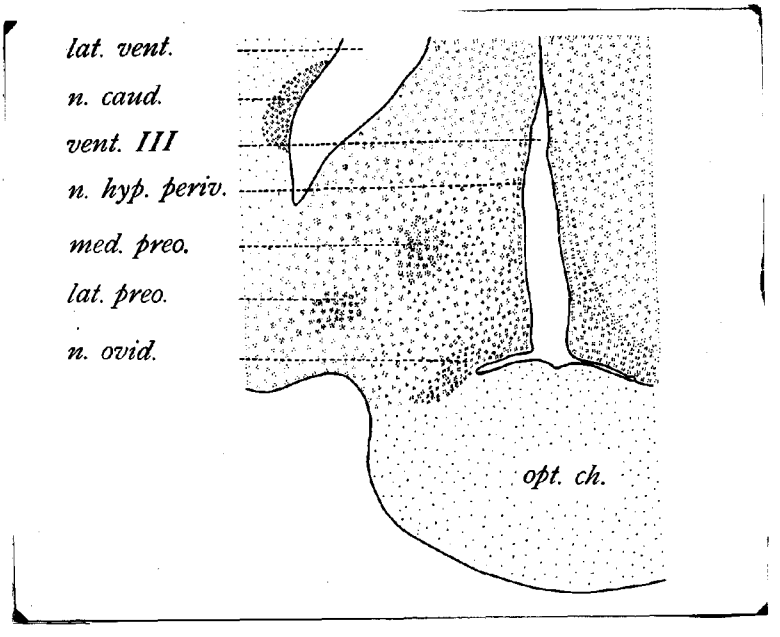

Fig. 1. Section through the anterior pole of the hypothalamus. Magnified 10 times.

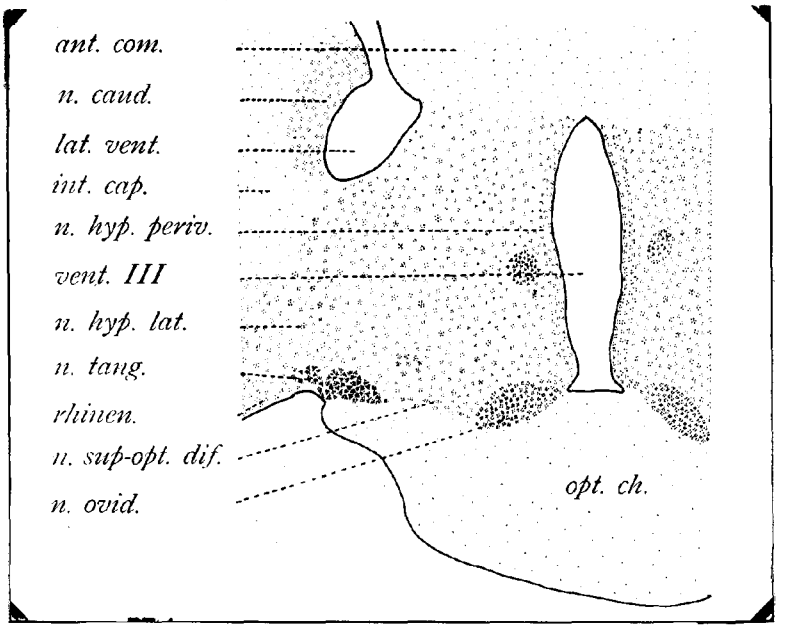

Fig. 2. Section through the middle of the Nucleus Ovoideus. Magnified 10 times.

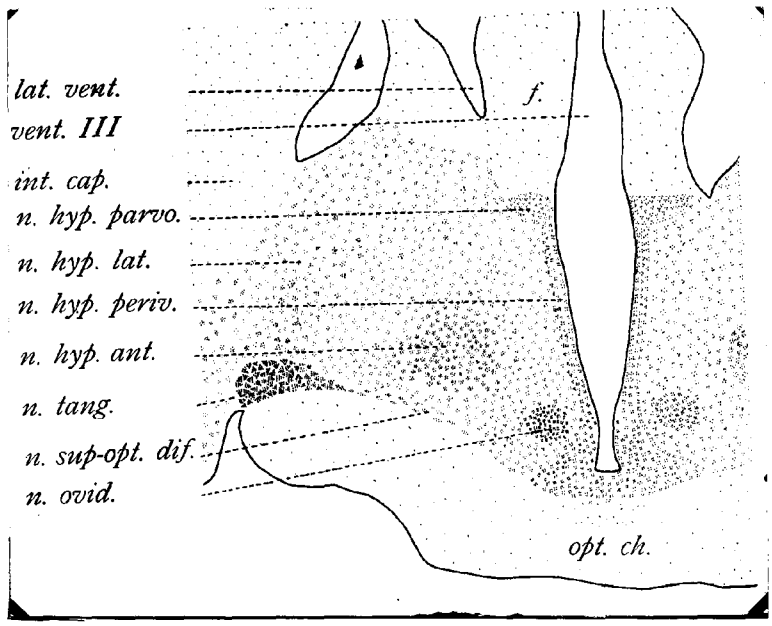

Fig. 3. Section through the anterior third of the Nucleus Tangentialis. Magnified 10 times.

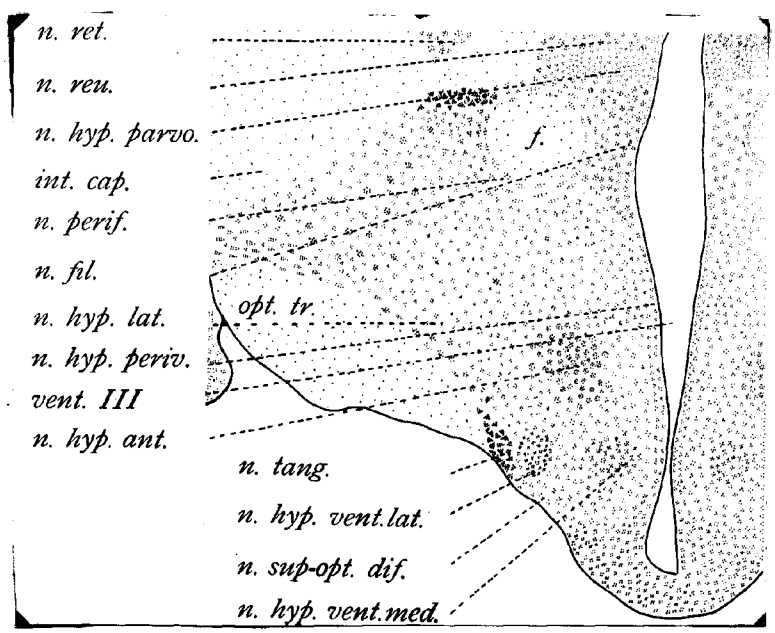

Fig. 4. Section through the posterior third of the Nucleus Tangentialis. Magnified 10 times.

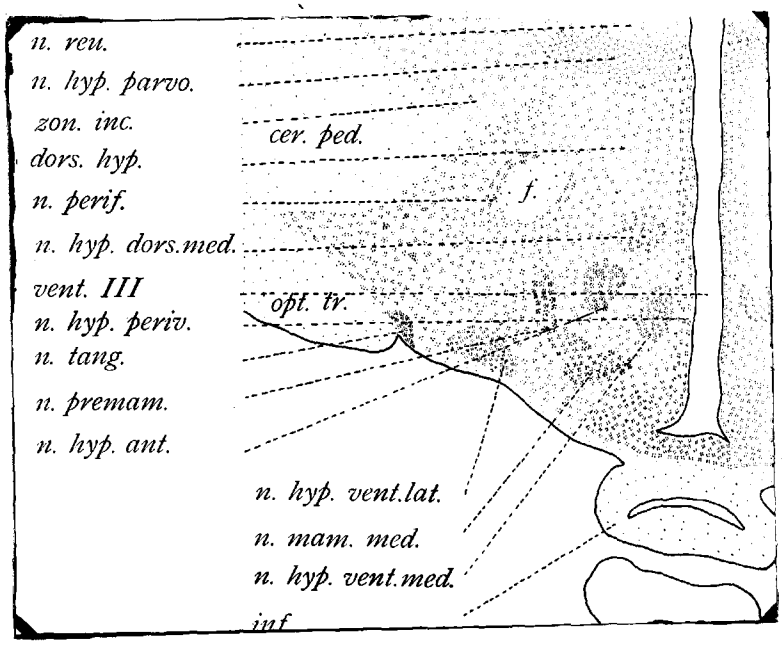

Fig. 5. Section through the posterior pole of the Nucleus Tangentialis. Magnified 10 times.

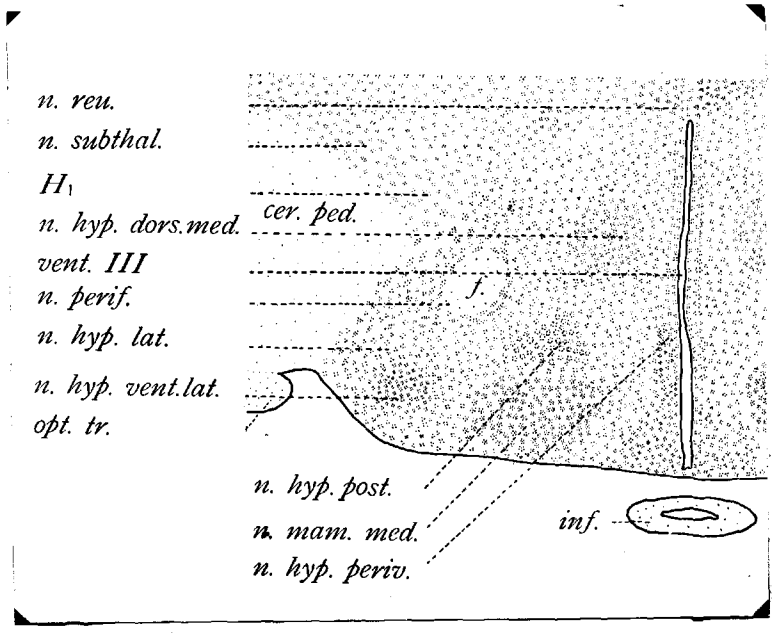

Fig. 6. Section through the middle of the Neucleus Hypothalamicus Posterior. Magnified 10 times.

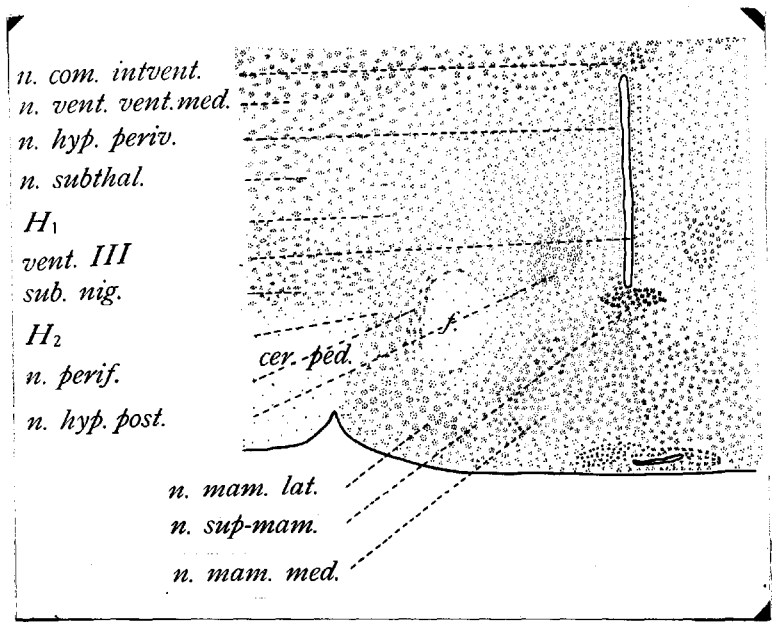

Fig. 7. Section through the middle of the Nucleus Mammillaris Medialis. Magnified 10 times.

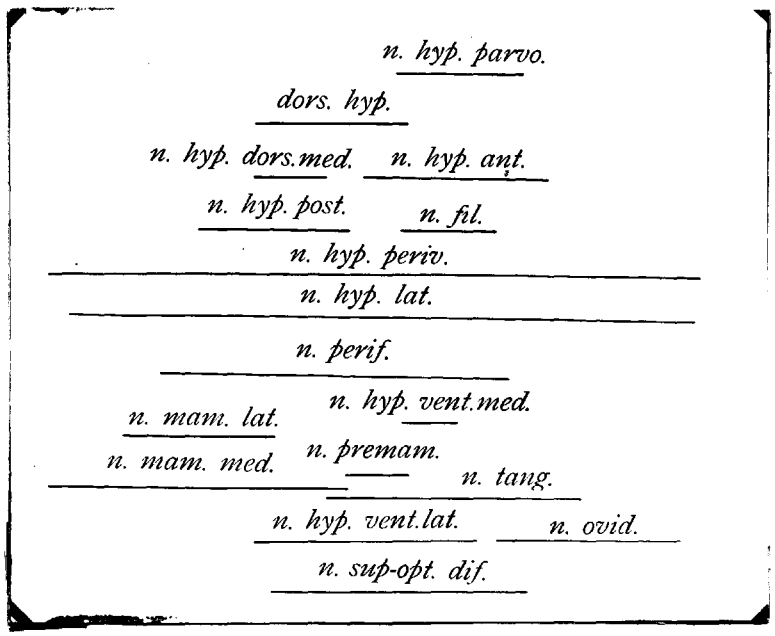

Fig. 8. Diagram showing anterior and posterior extent of the hypothalamic cell groups.