

# Automated Detection and Classification of Corneal Haze Using Optical Coherence Tomography in Patients With Keratoconus After Cross-Linking

Ahmad R. Dhaini, PhD,\* Maamoun Abdul Fattah, MD,† Sara Maria El-Oud, MS,\* and Shady T. Awwad, MD†

**Purpose:** To evaluate a proposed technology for offering objective grading and mapping of corneal haze as detected by corneal spectral domain optical coherence tomography after corneal cross-linking.

**Methods:** This was a retrospective study to evaluate corneal optical coherence tomography images performed on 44 eyes of 44 patients who underwent corneal cross-linking between January 2014 and May 2015, at the American University of Beirut Medical Center.

**Results:** Overall average brightness of the cornea was markedly increased from 43.4% ( $\pm 6.0$ ) at baseline to 50.2% ( $\pm 4.4$ ) at 1 month, 47.9% ( $\pm 4.4$ ) at 3 months, and 46.4% ( $\pm 5.7$ ) at 6 months with  $P < 0.001$ ,  $< 0.001$ , and 0.005, respectively. In the anterior stroma, the average brightness significantly increased at 1, 3, and 6 months with values of 54.8% ( $\pm 3.9$ ), 52.5% ( $\pm 5.2$ ), and 49.7% ( $\pm 6.9$ ) with  $P < 0.001$ ,  $< 0.001$ , and 0.003, respectively. In the mid stroma, the change was clinically significant at 1 and 3 months, whereas in the posterior stroma, it was only significant at 1 month compared with baseline ( $P = 0.003$ ). Overall, haze was mostly present at 1 month after surgery in all regions, especially in the anterior (32.1%;  $\pm 19.2$ ) and mid stromal regions (9.1%;  $\pm 18.8$ ),  $P < 0.001$  and 0.001, respectively. In contrast, haze in the posterior stromal region peaks at 3 and 6 months after surgery.

**Conclusions:** Anterior stromal haze was the greatest in intensity and area and it was present for a longer time span than mid and posterior stromal haze. At 12 months, the anterior stroma had still more haze intensity than preoperatively. This image-based software can provide objective and valuable quantitative measurements of corneal haze, which may impact clinical decision-making after different corneal surgeries.

**Key Words:** corneal haze, cross-linking, novel software, haze detection, haze classification

(*Cornea* 2018;37:863–869)

Corneal haze is a condition resulting from several pathological conditions, the most common being infectious and iatrogenic processes, mainly surgical interventions. The latter comprise photorefractive keratectomy and corneal cross-linking (CXL), among others.<sup>1–6</sup> The assessment of corneal haze has historically been subjective based on slit-lamp biomicroscopic evaluation and using rough, very subjective grading methods such as the Fantes methodology.<sup>7</sup> The latter is often confounded by the amount of slit-lamp illumination, contrast, and personal bias of the examiner. A more objective haze assessment is corneal densitometry analysis, which has been used by Scheimpflug tomographers to assess the amount of light scatter by the cornea. The output is expressed in grayscale units (GSUs).<sup>8,9</sup> The GSU scale is calibrated by proprietary software, which defines a minimum light scatter of 0 (maximum transparency) and maximum light scatter of 100 (minimum transparency). Optical coherence tomography (OCT) recently has been a great tool to accurately and objectively assess corneal haze and the inflammatory status of both anterior and posterior segments because of its higher resolution compared with Scheimpflug imaging.<sup>10,11</sup> However, a unified system interpreting the findings has been lacking, making it difficult to evaluate changes in corneal haze and interpret aggregate data.

In this study, we evaluate the ability of a novel software program developed by the authors at the American University of Beirut to grade and map corneal haze as detected by corneal OCT after CXL and compared its output with human operators' scores. Software has a role to establish an accurate, objective, and standardized method in evaluating corneal haze, in a repeatable and reproducible way.

## MATERIALS AND METHODS

### Patient Selection

This study retrospectively evaluated corneal OCT images performed on eyes of patients who underwent CXL between January 2014 and May 2015, at the American University of Beirut Medical Center in Lebanon. Corneal

Received for publication October 14, 2017; revision received January 18, 2018; accepted January 29, 2018. Published online ahead of print March 13, 2018.

From the \*Department of Computer Science, American University of Beirut, Beirut, Lebanon; and †Department of Ophthalmology, American University of Beirut Medical Center, Beirut, Lebanon.

The authors have no funding or conflicts of interest to disclose.

The authors have filed a patent for the image recognition software under the American University of Beirut.

Correspondence: Shady T. Awwad, MD, Cornea and Refractive Surgery Division, Department of Ophthalmology, American University of Beirut Medical Center, Cairo St, PO Box 110236, Beirut, Lebanon 1107 2020 (e-mail: sawwad@gmail.com).

Copyright © 2018 Wolters Kluwer Health, Inc. All rights reserved.

OCT was performed as part of their routine postoperative protocol measurements. Inclusion criteria were keratoconus eyes of patients aged 14 years and older, who underwent CXL at American University of Beirut Medical Center because of disease progression, and had completed all follow-up examinations through the first postoperative year. Keratoconus progression was defined as an increase in the steepest keratometric value (Kmax) of at least 1 diopter (D) in 1 year, or a mean central corneal thickness (CCT) decrease of  $\geq 5\%$  in 6 months, all observed in 3 consecutive tomographic measurements. Exclusion criteria were intraocular pressure of  $>21$  mm Hg, active ocular pathology, corneal thickness  $<400$   $\mu\text{m}$  at the thinnest point, preexisting corneal opacification/scars, history of keratitis, peripheral marginal degeneration, previous corneal and/or intraocular surgeries, and autoimmune and/or connective tissue disease. In our retrospective review, 44 eyes of 44 patients were selected. A total of 52 eyes were reviewed, but 8 eyes were excluded, because 3 eyes had a CCT  $<400$   $\mu\text{m}$  at the thinnest point and 5 eyes had previous corneal surgeries (intracorneal ring segments). All patients underwent a complete ophthalmic examination as part of their routine workup before CXL, including corneal topography and corneal OCT. This study was approved by the Institutional Review Board at the American University of Beirut and adhered to the Declaration of Helsinki principles.

### Corneal Cross-Linking

CXL was performed according to the Dresden protocol.<sup>12</sup> The eye to be treated was anesthetized by applying proparacaine hydrochloride 0.5% drops on 2 occasions at 5 minutes intervals. After positioning the patient under the operating microscope, an eyelid speculum was inserted and the central 9-mm corneal epithelium was removed with a blunt spatula. A mixed riboflavin 0.1% to 20% dextran solution (IROC Innocross AG, Zurich, Switzerland) was instilled every 2 minutes until the riboflavin penetrated the corneal stroma (ie, approximately 30 min). An ultraviolet lamp (UV-X; IROC AG) was then focused on the apex of the cornea at a distance of 5 cm for a total of 30 minutes, providing a mean radiant energy of 3.0 mW/cm<sup>2</sup>. The required irradiance was calibrated before each treatment. Riboflavin drops were applied to the cornea every 2 minutes during the total period of ultraviolet irradiation.

After treatment, the eye was irrigated with a balanced salt solution and a drop of gatifloxacin 0.3% was instilled, followed by placement of a bandage soft contact lens, which was kept for at least 4 days until complete epithelialization ensued as judged by slit-lamp microscopy. Postoperatively, patients were instructed to instill 1 drop of gatifloxacin 0.3% 4 times daily for 2 weeks with 1 drop of tobramycin-dexamethasone 0.1% 4 times daily for 1 week, and then 1 drop of fluorometholone 0.1% 4 times daily, tapered over 6 weeks.

### OCT Measurements

The Cirrus high-definition OCT (Cirrus HD-OCT; Carl Zeiss Meditec, Inc, Dublin, CA) was used in the anterior

segment cube 512  $\times$  128 mode.<sup>13</sup> Corneal OCT measurements (120 sections of the cube 4-  $\times$  4-mm videos) were evaluated at baseline and at 1, 3, 6, and 12 months after CXL by dedicated corneal OCT image analysis software developed by the authors.

### Software Analysis of Haze in OCT Sections

To permit automated objective detection and classification of corneal haze, we developed a software solution, which performs custom image analysis techniques and uses methods from the image-processing library OpenCV (OpenCV version 3.1: Image processing software, December 2015). The new software takes as input OCT images from the video files of the corneal OCT cube sections and provides 2 types of outputs: 1) the OCT image with visual annotations that reflect the detection and classification of haze and 2) statistics about haze.<sup>14</sup> The detection and classification of corneal haze in an OCT image is achieved by the automated solution using the following steps:

1. Loading the OCT image/video into the program (Figure 1A)
2. Detecting corneal boundaries (excluding the epithelium) (Figure 1B)
3. Computing corneal properties such as area(s), intensity, and average brightness
4. Splitting the cornea into 3 regions (the cornea was arbitrarily divided to 3 equal parts depending on the central thickness from the Bowmen to endothelial layer):
  - 1) anterior stroma; 2) mid stroma; 3) posterior stroma.
5. Detecting haze regions (contours) (Figure 1C)
6. Aggregating "close" haze regions
7. Classifying haze into corresponding region(s) (Figure 1D)

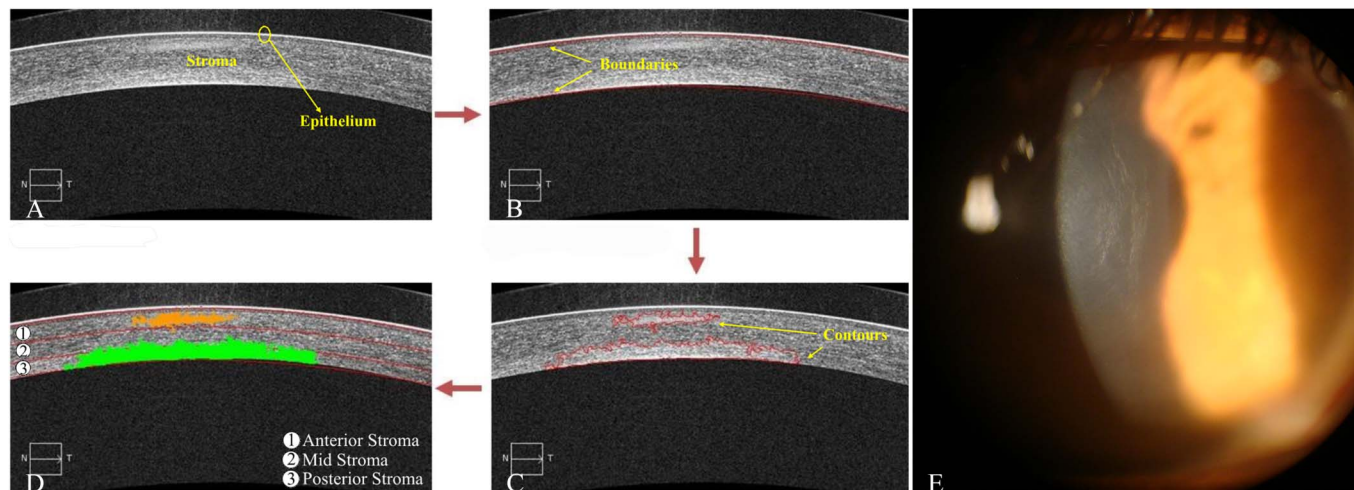
### Statistical Analysis

The sample size was calculated based on a previously calculated standard deviation of 4.03 GSU for central corneal haze after CXL using Scheimpflug tomography<sup>15</sup>; using 95% confidence interval and 1.25 GSU being the margin of error, the minimum computed sample size was 40 eyes. Statistical analysis was performed using SPSS version 21.0 (SPSS Inc, Chicago, IL), and Microsoft Office Excel was used for data management and analyses. Descriptive statistics were reported as mean and SDs for continuous variables. The paired *t* test was used to compare haze intensity and area between different time points. Two-way repeated-measures analysis of variance (ANOVA) with the Bonferroni correction for post hoc analysis was used to compare the change in haze after CXL.  $P < 0.05$  was considered statistically significant unless otherwise stated.

## RESULTS

### Demographics

The OCT measurements that were analyzed by software belonged to 44 eyes of 44 patients (30 males and



**FIGURE 1.** Four main steps software uses to detect and classify haze: (A) loading OCT image, (B) detection of corneal boundaries, (C) detecting haze contour, and (D) splitting the cornea into 3 regions and classifying haze. E, Slit-lamp photograph of the cornea reflecting stromal haze seen on OCT.

14 females; mean age  $22.0 \pm 6.1$  yrs). Ten eyes (22.7%) had grade 1 keratoconus according to the Amsler–Krumeich classification, 28 eyes (63.6%) had grade 2, and 6 eyes (13.6%) had grade 3. The average preoperative CCT and Kmax of the recruited eyes were  $465.60 \pm 43.55 \mu\text{m}$  and  $54.79 \pm 4.70$  D, respectively.

**Corneal Haze by OCT-Based Software**

Corneal haze was assessed by 3 parameters: intensity of haze, percentage of the area occupied by haze, and haze location: anterior, mid, and posterior stroma.

**Haze Intensity**

Table 1 shows the average brightness of different corneal regions and the total aggregate, for all eyes, collected at different periods of time, expressed in per-

centage. The overall average brightness markedly increased compared with the baseline value at 1, 3, and 6 months periods with  $P < 0.001$ ,  $< 0.001$ , and  $0.005$ , respectively. In the anterior stromal region, the average brightness significantly changed at 1, 3, and 6 months with  $P < 0.001$ ,  $< 0.001$ , and  $0.003$ , respectively. The average increase in brightness in the mid stromal region was clinically significant at 1 and 3 months with  $P < 0.001$  and  $0.048$ , respectively. Finally, the average brightness in the posterior stroma was only clinically significant at the 1-month period compared with baseline ( $P = 0.003$ ) (Figure 2 and Table 1).

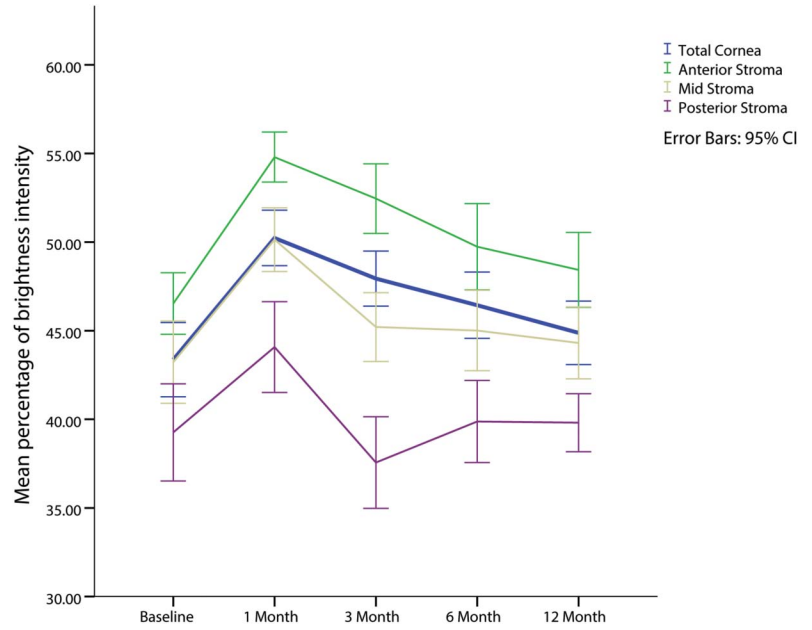
**Area Occupied by Haze**

Figure 3 shows the trend in the corneal haze location and area occupied by haze. Overall, haze was mostly present at 1 month after surgery for all regions, especially in the

**TABLE 1.** Percentage of Brightness Intensity in Each Corneal Region After CXL

	Anterior Stroma	Middle Stroma	Posterior Stroma	Total Cornea
Baseline	46.5 ( $\pm 4.9$ )	43.2 ( $\pm 6.7$ )	39.2 ( $\pm 7.8$ )	43.3 ( $\pm 6.0$ )
	33.5–59.5	30.5–56.3	25.1–53.6	30.3–54.9
At 1 month	54.7 ( $\pm 3.9$ )	50.1 ( $\pm 5.0$ )	44.0 ( $\pm 7.2$ )	50.2 ( $\pm 4.4$ )
	43.7–62.8	35.9–58.9	28.5–65.3	36.7–59.8
	$P < 0.001$	$P < 0.001$	$P = 0.005$	$P = 0.149$
At 3 months	52.4 ( $\pm 5.2$ )	45.2 ( $\pm 3.6$ )	37.5 ( $\pm 4.8$ )	47.9 ( $\pm 4.4$ )
	41.3–65.2	39.5–53.2	31.7–49.1	38.8–57.1
	$P < 0.001$	$P < 0.001$	$P = 0.003$	$P = 0.091$
At 6 months	49.7 ( $\pm 6.9$ )	45.0 ( $\pm 6.6$ )	39.8 ( $\pm 7.0$ )	46.4 ( $\pm 5.7$ )
	28.1–60.1	29.5–57.9	24.3–57.7	30.6–55.9
	$P < 0.001$	$P = 0.048$	$P = 0.169$	$P = 0.31$
At 12 months	48.4 ( $\pm 6.4$ )	44.3 ( $\pm 5.8$ )	39.8 ( $\pm 4.8$ )	44.8 ( $\pm 5.3$ )
	29.8–68.5	31.5–57.5	26.1–50.3	32.6–57.5
	$P = 0.003$	$P = 0.146$	$P = 0.727$	$P = 0.645$

Downloaded from http://journals.lww.com/corneajrnl by BHDMSepPHKav1ZEquumr1CINda+kULHEZgbsHo4XMM10nCy wCX1AWNvYQp/1QIHHD3D00DRy7TvsSF14Cf3Vc1y0abggQZxdwmfKZBYwvs on 08/21/2024



**FIGURE 2.** Mean percentage of brightness intensity in the 3 regions of the cornea (anterior, mid, and posterior stroma) and the total cornea over 12 months after cross-linking. One-way ANOVA with the Bonferroni correction over time, 1 to 12 months:  $P < 0.001$  for the total cornea, anterior, mid, posterior stroma and  $P = 0.007$  for the posterior stroma.

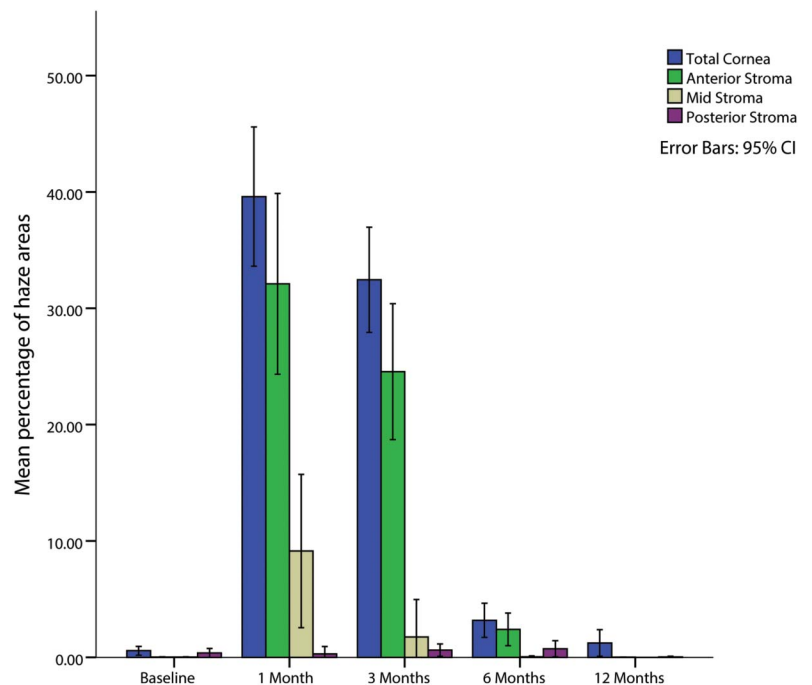
anterior and mid stromal regions. In contrast, haze in the posterior stromal region peaks at 3 and 6 months after surgery (Table 2).

### Corneal Haze as Graded by Clinicians at the Slit-Lamp

The variation of haze, as determined by the slit lamp, was plotted over time and is shown in Figure 4. At baseline, all the patients had clinical haze of grade 0. After CXL, haze was more severe at 1 month (ie, more eyes had grade 1+ and grade 2+) compared with the 3-, 6-, and 12-month follow-up visits.

### Case Example

To highlight the ability of the new software to aid in clinical analysis and decision-making for tracking each patient's haze progress over time, Figure 5 serves as a case example: In general, haze peaked at 1 and 3 months after surgery compared with baseline. Posterior haze developed directly after treatment (1 mo), then haze mainly occupied the anterior part of the cornea between the first and third months. After this period, it significantly decreased to preoperative values at 6 and 12 months postoperatively after a topical steroid treatment course.



**FIGURE 3.** Percentage area occupied by haze in the total cornea and subdivided into anterior, mid, and posterior stroma and the change of area over a 12-month period after cross-linking.

Downloaded from http://journals.lww.com/corneajnl by BHD/MSepPHKav1zEoum1t0INda+kULHEZgbsH04XM10n0CjwCX1AWN1YQp/1QIHID3D00QRy7L7vSF14CF3V/C1y0abggQZXdwmfKZBYrws= on 08/21/2024

**TABLE 2.** Percentage of Haze Area in Each Corneal Area After CXL

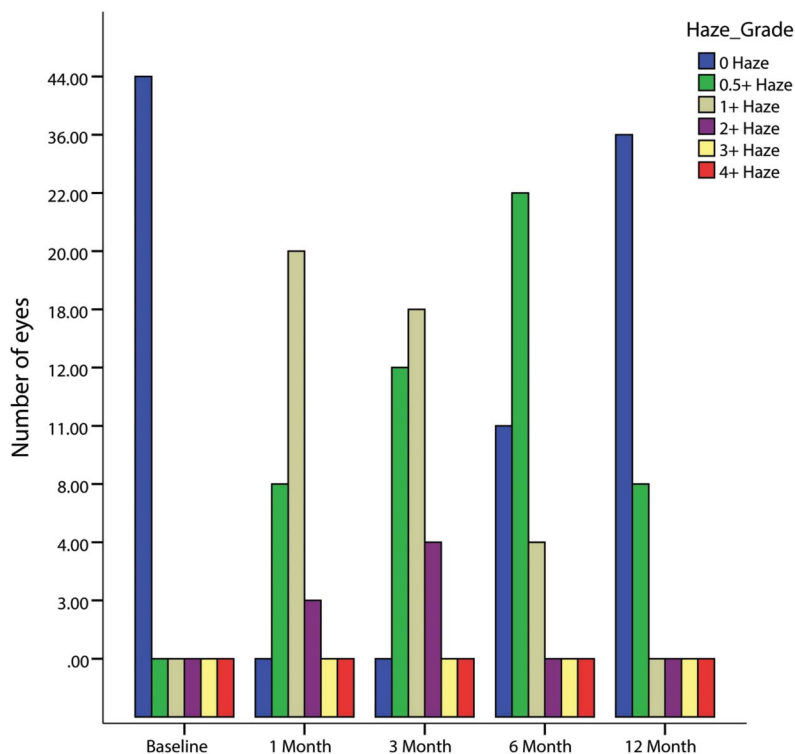
	Anterior Stroma	Middle Stroma	Posterior Stroma	Total Cornea
Baseline	0.0 (±0.1) 0.0–0.6	0.0 (±0.1) 0.0–0.8	0.3 (±1.2) 0.0–6.2	0.5 (±1.2) 0.0–6.2
At 1 month	32.1 (±19.2) 0.0–63.0 <i>P</i> < 0.001	9.1 (±18.8) 0.0–54.7 <i>P</i> = 0.001	0.3 (±1.3) 0.0–6.3 <i>P</i> = 0.763	39.6 (±15.1) 0.1–63.0 <i>P</i> < 0.001
At 3 months	24.5 (±15.3) 0.0–51.9 <i>P</i> < 0.001	1.7 (±9.1) 0.0–52.3 <i>P</i> = 0.153	0.6 (±1.4) 0.0–5.9 <i>P</i> = 0.383	32.4 (±10.9) 10.6–52.3 <i>P</i> < 0.001
At 6 months	2.3 (±4.2) 0.0–17.2 <i>P</i> < 0.001	0.0 (±0.2) 0.0–1.2 <i>P</i> = 0.051	0.7 (±2.0) 0.0–9.2 <i>P</i> = 0.304	3.1 (±4.4) 0.0–17.2 <i>P</i> < 0.001
At 12 months	0.0 (±0.1) 0.0–0.3 <i>P</i> = 0.685	0.0 (±0.0) 0.0–0.0 <i>P</i> = 0.241	0.0 (±0.1) 0.0–0.9 <i>P</i> = 0.063	1.2 (±3.6) 0.0–20.1 <i>P</i> = 0.236

**DISCUSSION**

It is interesting that an objective classification of haze for practical clinical purposes has not yet been developed. This is more notable especially after the recent popularity of procedures that require objective and accurate assessment of corneal haze such as CXL and photorefractive keratectomy in irregular corneas, especially when combined with or performed after previous CXL. Most clinical studies evaluating results of the foregoing procedures use clinical-based grading performed on the slit-lamp (such as Fantes grading) or Scheimpflug-based GSU grading.<sup>7,9,16</sup> The problem with the former method is that it lacks standardization and is very

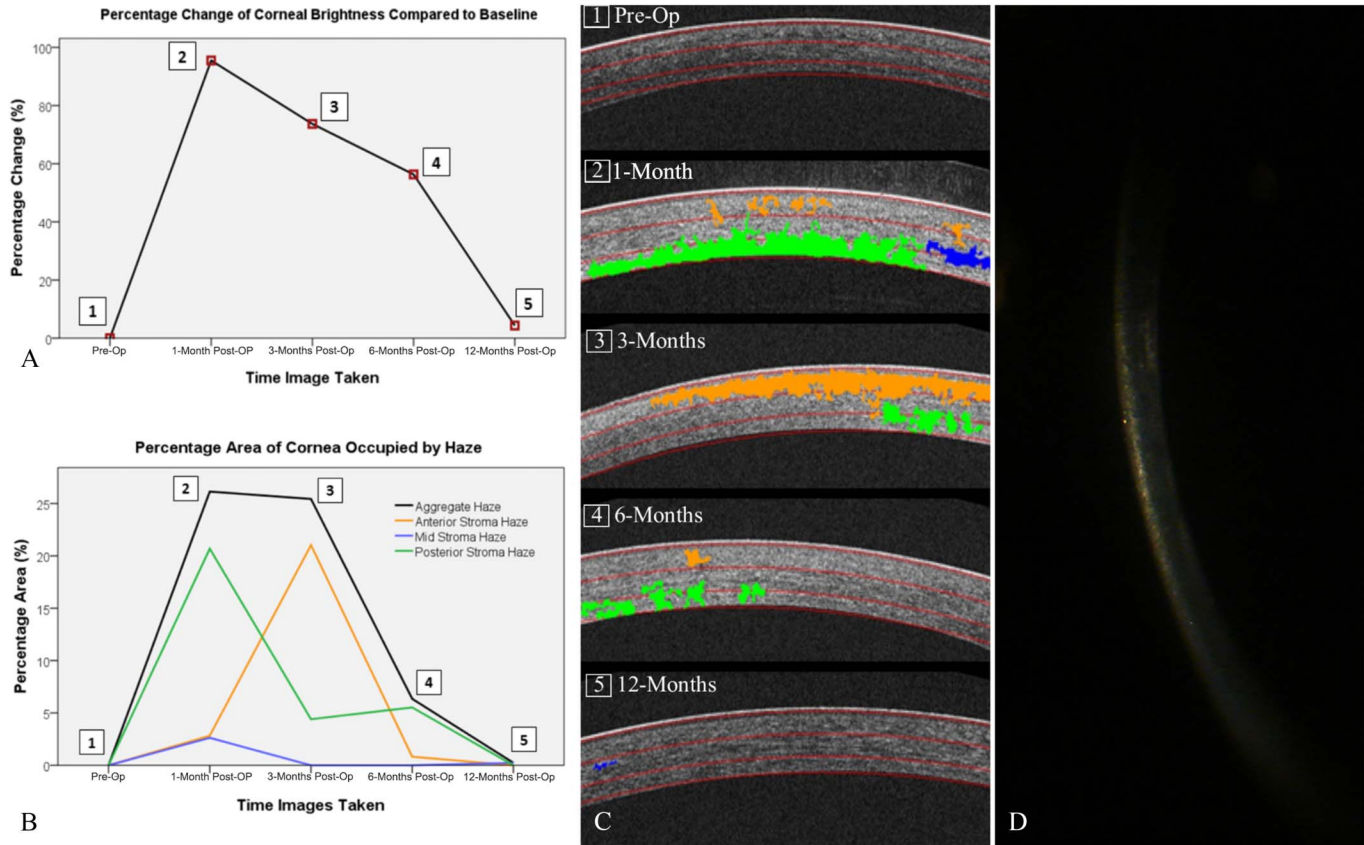
subjective and operator-, illumination-, and instrumentation-dependent, and no repeatability or reproducibility studies are available. Scheimpflug densitometric grading is a major improvement over the slit lamp-based grading, but it lacks high resolution and suffers from distortion and erroneous data resulting from potential light scattering and absorption associated with anterior or mid stromal haze.<sup>15–20</sup> Additionally, there is no dedicated software for analyzing the location (anterior, mid or posterior stroma, central or mid peripheral) and area of involvement.

Software developed by the authors is cloud-based and has been designed to analyze OCT cube videos and images



**FIGURE 4.** Bar chart showing the number of eyes and their corresponding haze grading as determined by slit-lamp at each time point over 12 months.

Downloaded from http://journals.lww.com/corneajrnl by BHDMSepHKav1zEoum1tQINda+kULHEZgbsHh04XMIONCjwCX1AWNyQp/IIQHID33D00QRy7TVSH4Cf3V/C1y0abggQZXdwmfKZBYrws= on 08/21/2024



**FIGURE 5.** Analysis of sample patient haze and corneal brightness over time. Haze of the analyzed patient peaks in intensity (A) and the area occupied (B) at 1 and 3 months after surgery compared with a preoperative condition, with a significant decrease to preoperative values at 6 and 12 months postoperatively after a topical steroid treatment course, as can be seen on serial OCT images (C). A slit-lamp microscopy image at 3 months showcases haze detected on OCT (D).

from the Zeiss Cirrus platform, but the method used can be tweaked to receive input from any commercially available OCT machine. The results shown and their overall correlation to Scheimpflug and slit-lamp grading indicate that OCT-based haze grading, using image analysis software, provides a standardized, objective, fast, and detailed information about haze intensity, area occupation, and location within the cornea.

Using OCT-based image analysis software, important haze trends after CXL can be detected. Although the highest mean intensity of haze was found to be at 1 month, then at 3 months, the largest mean area occupied by haze was at 1 month, except for the posterior stroma. Anterior stromal haze was largest in intensity and in area, and it was present for a longer time span than the mid and posterior stromal haze. At 12 months, the anterior stroma had still more haze intensity than preoperatively (not statistically significant), whereas the intensity in the remaining cornea returned to baseline. Additionally, important findings can be noted by examining individual scans. In Figure 5, posterior stromal haze intensity and area occupation peak at 1 month then taper down thereafter, whereas anterior and mid stromal haze becomes worse at 3 months. This finding denotes that posterior stromal haze is likely to be a direct effect of ultraviolet and free

radical injury, whereas haze in the remaining cornea seems to be a reaction to the injury, developing because of cell migration and additional haze production.

These observations were also noted in previously performed studies that used backscatter of light from the cornea to objectively measure haze. They showed comparable results to ours with regard to the intensity and course of haze.<sup>19,20</sup> The anterior stroma was also found to have the highest intensity and area of haze during the peak months (1–3 mo) compared with the mid and posterior cornea, which suggests that it is the most affected area in cross-linking, as previously noted.<sup>19,21</sup> Moreover, the software measures of corneal haze agree with our subjective grading of clinical haze and with results of previous studies reporting on CXL in keratoconus and corneal ectasia using Scheimpflug and human observers.<sup>22</sup> Both methods showed an increase in haze at 1 to 3 months followed by a subsequent decrease thereafter at 3 to 12 months.

One limitation of our study relates to corneal sector categorization. The corneal stroma was equally divided into anterior, mid, and posterior areas by a preset software feature. Although this classification has as for a purpose to group corneal haze in any corneal disease based on the relative geographic location, it could be improved by a depth-specific

classification, which would be more clinically relevant for eyes after cross-linking, especially in terms of proximity to the endothelium, and would be independent on initial corneal thickness.

With the widespread availability of OCT machines in many eye clinics, we would predict that OCT-based haze assessment may become the standard methodology for following patients with corneal haze and scar and in the analysis of aggregate data for research purposes. Software based on image analysis can provide valuable and objective information, and can have a great potential for further improvements. In an era of proliferating CXL techniques, from variably accelerated to transepithelial to iontophoresis, to different newly devised agents, to customized photorefractive keratectomy and CXL (sequential or combined), an objective assessment of corneal haze is key to evaluating the safety of these emerging techniques.

## REFERENCES

- Hanna KD, Poulighen YM, Waring GO III, et al. Corneal wound healing in monkeys after repeated excimer laser photorefractive keratectomy. *Arch Ophthalmol*. 1992;110:1286–1291.
- van de Pol C, Soya K, Hwang DG. Objective assessment of transient corneal haze and its relation to visual performance after photorefractive keratectomy. *Am J Ophthalmol*. 2001;132:204–210.
- Erie JC, Patel SV, McLaren JW, et al. Corneal keratocyte deficits after photorefractive keratectomy and laser in situ keratomileusis. *Am J Ophthalmol*. 2006;141:799–809.
- Lee YG, Chen WY, Petroll WM, et al. Corneal haze after photorefractive keratectomy using different epithelial removal techniques: mechanical debridement versus laser scrape. *Ophthalmology*. 2001;108:112–120.
- Kim BZ, Jordan CA, McGhee CN, et al. Natural history of corneal haze after corneal collagen crosslinking in keratoconus using Scheimpflug analysis. *J Cataract Refract Surg*. 2016;42:1053–1059.
- Takacs AI, Mihaltz K, Nagy ZZ. Corneal density with the pentacam after photorefractive keratectomy. *J Refract Surg*. 2011;27:269–277.
- Fantes FE, Hanna KD, Waring GO III, et al. Wound healing after excimer laser keratomileusis (photorefractive keratectomy) in monkeys. *Arch Ophthalmol*. 1990;108:665–675.
- Boulze-Pankert M, Dariel R, Hoffart L. Corneal Scheimpflug densitometry following photorefractive keratectomy in myopic eyes. *J Refract Surg*. 2016;32:788–791.
- Cennamo G, Forte R, Aufiero B, et al. Computerized Scheimpflug densitometry as a measure of corneal optical density after excimer laser refractive surgery in myopic eyes. *J Cataract Refract Surg*. 2011;37:1502–1506.
- Wang J, Simpson TL, Fonn D. Objective measurements of corneal light-backscatter during corneal swelling, by optical coherence tomography. *Invest Ophthalmol Vis Sci*. 2004;45:3493–3498.
- Zarranz-Ventura J, Keane PA, Sim DA, et al. Evaluation of objective vitritis grading method using optical coherence tomography: influence of phakic status and previous vitrectomy. *Am J Ophthalmol*. 2016;161:172–180.
- Wollensak G, Spoerl E, Seiler T, et al. Riboflavin/ultraviolet-a-induced collagen crosslinking for the treatment of keratoconus. *Am J Ophthalmol*. 2003;135:620–627.
- Rodrigues EB, Johanson M, Penha FM. Anterior segment tomography with the cirrus optical coherence tomography. *J Ophthalmol*. 2012;2012:806989.
- Dhaini AR, Chokr M, El-Oud S, et al, inventors; “System and method for automated detection of corneal haze and demarcation line in optical coherence tomography images”, US patent 6161–021. June 16, 2017.
- Antonios R, Fattah MA, Maalouf F, et al. Central corneal thickness after cross-linking using high-definition optical coherence tomography, ultrasound, and dual Scheimpflug tomography: a comparative study over one year. *Am J Ophthalmol*. 2016;167:38–47.
- McLaren JW, Wacker K, Kane KM, et al. Measuring corneal haze by using Scheimpflug photography and confocal microscopy. *Invest Ophthalmol Vis Sci*. 2016;57:227–235.
- Huebscher H, Fink W, Steinbruck D, et al. Scheimpflug records without distortion—a mythos? *Ophthalmic Res*. 1999;31:134–139.
- Mencucci R, Paladini I, Virgili G, et al. Corneal thickness measurements using time-domain anterior segment OCT, ultrasound, and Scheimpflug tomographer pachymetry before and after corneal cross-linking for keratoconus. *J Refract Surg*. 2012;28:562–566.
- Alnawaiseh M, Rosentreter A, Eveslage M, et al. Changes in corneal transparency after cross-linking for progressive keratoconus: long-term follow-up. *J Refract Surg*. 2015;31:614–618.
- Gutierrez R, Lopez I, Villa-Collar C, et al. Corneal transparency after cross-linking for keratoconus: 1-year follow-up. *J Refract Surg*. 2012;28:781–786.
- Kymionis GD, Grentzelos MA, Plaka AD, et al. Correlation of the corneal collagen cross-linking demarcation line using confocal microscopy and anterior segment optical coherence tomography in keratoconic patients. *Am J Ophthalmol*. 2014;157:110–115.
- Greenstein SA, Fry KL, Bhatt J, et al. Natural history of corneal haze after collagen crosslinking for keratoconus and corneal ectasia: Scheimpflug and biomicroscopic analysis. *J Cataract Refract Surg*. 2010;36:2105–2114.