

Case Report

Large Tick (*Ixodes*) Infestation of the Upper Eyelid Presenting as Eyelid Mass and Preseptal Cellulitis

Mahmoud O. Jaroudi^a Ahmad M. Mansour^a Riad Ma'luf^a
Alessandro Meduri^b Ayman Tawil^c Muhammad H. Younis^a

^aDepartment of Ophthalmology, American University of Beirut, Beirut, Lebanon;

^bDepartment of Surgical Specialties, Ophthalmology Clinic, University of Messina,

Messina, Italy; ^cDepartment of Pathology, American University of Beirut, Beirut, Lebanon

Keywords

Preseptal cellulitis · Tick · Eyelid mass

Abstract

A child was referred for removal of an eyelid mass. She had preseptal cellulitis and a large tick deeply embedded in the tarsus of the upper eyelid necessitating antibiotic therapy and en-bloc excision of the tick with the attached eyelid portion. Large ticks that are embedded in the eyelid are best treated surgically with en-bloc excision of the tick and its attached lid. On the contrary, for small ticks involving the very superficial skin, fine-tipped tweezers can be used to grasp the insect. Ticks are vectors of several diseases like Lyme borreliosis, hence prophylactic antibiotic treatment and close observation are recommended.

© 2019 The Author(s)
Published by S. Karger AG, Basel

Introduction

Tick infestations of the eyelid are a rare occurrence and clinicians are somewhat unfamiliar with the optimal medical and surgical management of this condition. Current management of a very large tick of the eyelid is presented.

Case Presentation

An 8-year-old girl presented with total ptosis of the left eyelid and periorbital inflammation reaching the lateral aspect of the face. She was referred with the diagnosis of eyelid tumor. The patient's mother reported noticing a small foreign body protruding from her daughter's eyelid which was increasing gradually in size over the course of 5 days. The girl was otherwise healthy with no history of trauma or recent travel. However, the patient had a school trip to an animal farm few days prior to the onset of her symptoms. Slit-lamp exam revealed a large tick deeply anchored to the right upper eyelid (Fig. 1). En-bloc excision under local anesthesia was performed, and the patient was started prophylactically on oral amoxicillin clavulanate 750 mg for 10 days (antibiotic prophylaxis for Lyme disease). No culture of eyelid biopsy was taken as there was no evidence of bacterial cellulitis. The tick was identified by the Biology Department to belong to the *Ixodes* species. Pathology revealed a severe acute and chronic inflammatory reaction of the eyelid (diffuse infiltrate composed of an admixture of lymphocytes, histiocytes, plasma cells, and neutrophils) (Fig. 2). The eyelid ptosis and surrounding inflammatory reaction resolved completely 1 week postoperatively.

Discussion

The current case appears to show one of the largest ticks reported in the ophthalmic literature [1–11], and one of the larger species of the genus *Ixodes* that infects ruminants consistent with the girl's farm trip. The *Ixodes* genus refers to hard-bodied ticks of the family *Ixodidae* that have important disease (*Borrelia burgdorferi*, *babesiosis*, and *anaplasmosis*) vectors of animals or humans. In addition, these ticks can inject a variety of toxins that can dysregulate platelet aggregation or the coagulation cascade [1]. Feeding is continuous with pulses of salivation that include the toxins alternating with periods of feeding. It is important to consider antibacterial prophylaxis following tick removal as ticks are blood-sucking ectoparasites and vectors of bacteria, viruses and rickettsia (Lyme borreliosis, Rocky Mountain spotted fever, tick-borne encephalitis, and relapsing fever) [1, 2, 3, 8, 11].

A debate exists around the technique of tick removal because of the risk of further injection of noxious substances by the stressed tick or by leaving tick's mouthparts embedded in the skin [4, 9, 10]. Compressing the body of the tick and forceful removal with forceps could lead to release of large amount of toxins with possible anaphylactic shock. Also, the hypostome or tick head may stay attached to the host with granuloma formation. Hence, our surgical approach hereby included total excision of the tick with its attached eyelid [4, 8, 9]. On the contrary, if the tick is attached to the superficial skin, especially in remote rural areas with no medical services, certain precautionary principles for small tick removal include avoiding unnecessary manipulation of the tick, grasping very firmly the tick's mouthparts as close to the skin as possible, and cleaning the lesion after tick removal [4]. Anaphylactic reactions can occur rarely and need paramedical assistance [2, 3]. Other techniques for removal of ticks for other skin sites include extraction, applying focal heat to induce release, and smothering the tick with petrolatum to induce release.

Statement of Ethics

Written patient consent was obtained.

Disclosure Statement

The authors have no conflicts of interest to disclose.

Funding Sources

No funding was received.

Author Contributions

All authors attest that they meet the current ICMJE criteria for authorship.

References

- 1 Barker SC, Walker AR. Ticks of Australia. The species that infest domestic animals and humans. *Zootaxa*. 2014 Jun;3816(3816):1–144.
- 2 Stone BF, Binnington KC, Gauci M, Aylward JH. Tick/host interactions for *Ixodes holocyclus*: role, effects, biosynthesis and nature of its toxic and allergenic oral secretions. *Exp Appl Acarol*. 1989 Jun;7(1):59–69.
- 3 Piesman J, Stone BF. Vector competence of the Australian paralysis tick, *Ixodes holocyclus*, for the Lyme disease spirochete *Borrelia burgdorferi*. *Int J Parasitol*. 1991 Feb;21(1):109–11.
- 4 Needham GR. Evaluation of five popular methods for tick removal. *Pediatrics*. 1985 Jun;75(6):997–1002.
- 5 Liolios V, Goldsmith C. Tick infestation on the lower eyelid: a case report. *Cases J*. 2009 Nov;2(1):9073.
- 6 Keklikçi U, Unlü K, Cakmak A, Akdeniz S, Akpolat N. Tick infestation of the eyelid: a case report in a child. *Turk J Pediatr*. 2009 Mar-Apr;51(2):172–3.
- 7 McLeod BK. Sheep tick in the eyelid. *Br J Ophthalmol*. 1986 Jan;70(1):75–6.
- 8 Price KM, Woodward JA. Management of tick infestation of the eyelid. *Ophthalm Plast Reconstr Surg*. 2009 Jul-Aug;25(4):328–30.
- 9 Park J, Suh E. Tick Infestation of the eyelid and removal with forceps and punch biopsy. *J Craniofac Surg*. 2016 Nov;27(8):2098–100.
- 10 Foo LL, Ting DS, Ng WY, Quah BL. Novel technique of dog tick removal from the eyelid. *Acta Ophthalmol*. 2016 Dec;94(8):e819–20.
- 11 John M, Raman M, Ryan K. A tiny tick can cause a big health problem. *Indian J Ophthalmol*. 2017 Nov;65(11):1228–32.

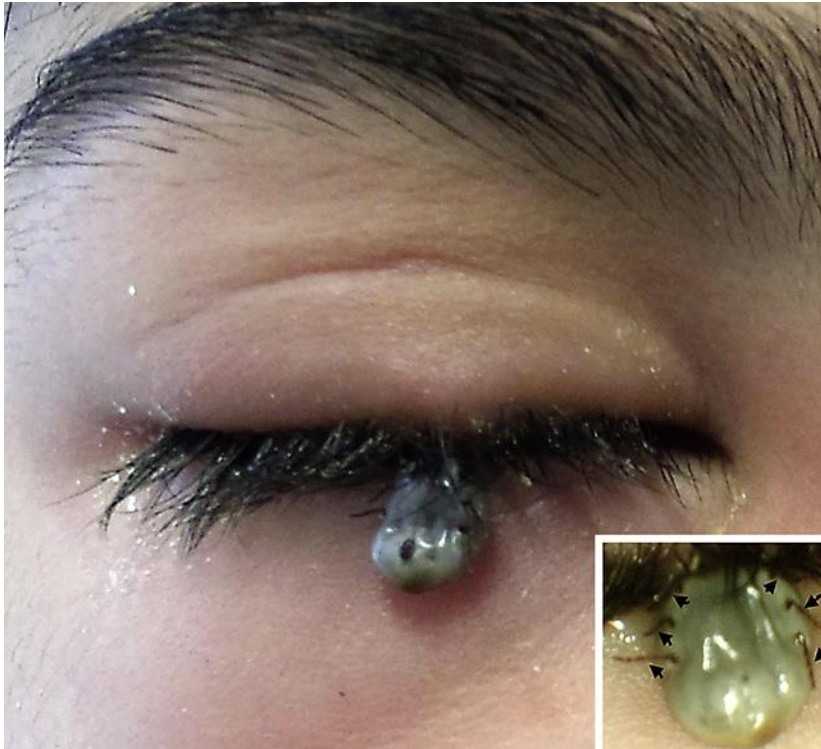

Fig. 1. Right periorbital swelling and redness with eyelid ptosis are shown. A large tick is seen with the dorsal side abutting the lower lid and the ventral side showing the inferior part with three pairs of legs (**inset**). The upper ventral side has its hypostome (central piercing element having hooks) inserted deep into the upper tarsus providing a very strong anchor to its host.

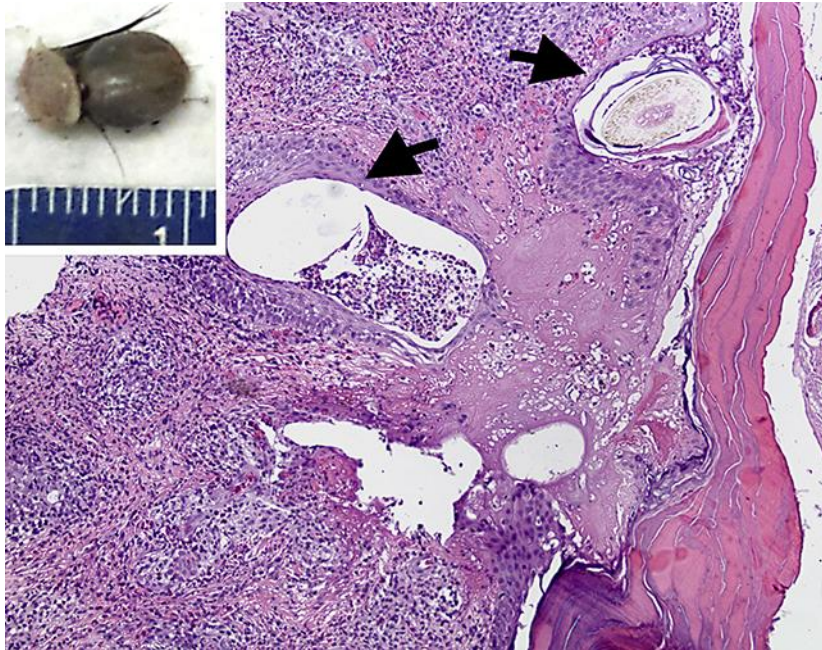


Fig. 2. Histologic section of the excised eyelid (PAS stain). The eyelid infiltrate is composed of an admixture of lymphocytes, histiocytes, plasma cells, and neutrophils. The tick hooks (arrows) are noted deep into the tarsus. The **inset** depicts the engorged adult tick measuring 8 mm in length.