

# Bilateral Carotid Patch Infection Occurring 12 years Following Endarterectomy

*Fady Haddad, Associate professor of clinical surgery, Mohamad-Rachad Wehbe, Fellow of vascular surgery, Caroline Hmedeh, Research assistant, Mouafak Homsy, Research Fellow, Rakan Nasreddine, Fellow of vascular surgery, and Jamal J. Hoballah, Professor of surgery, Hamra, Beirut, Lebanon*

**Background:** Carotid endarterectomy (CEA) is the most commonly used invasive procedure for treatment of carotid stenosis. Different methods are used to close the arteriotomy including primary closure and patch repair with a graft. Prosthetic patch infection is a rare but serious complication of patch closure, and we will present a unique case of carotid patch infection (CPI) 12 years after implantation.

**Case:** Patient is 76-year-old male ex-smoker with history of bilateral CEA with Dacron patch closure 12 years prior to presentation. He had a left neck draining sinus one year prior to presentation that was treated by patch excision and ICA ligation. He presented to us one year later with a right neck draining sinus tract, reaching the carotid sheath on CT scan. Surgery was done under EEG and NIRS oximetry with shunting. Excision of the patch with the involved ICA was done. CCA to distal ICA bypass was done by a reversed GSV graft. Intraoperative cultures of the patch grew *Staphylococcus* species coagulase negative, so the patient was discharged on antibiotics for one month. The patient had early postoperative swallowing difficulty that resolved over six weeks but no other complications. Patient was followed-up every three months and he was doing well on one-year follow-up.

**Discussion:** Carotid patch infection is a well-documented complication of CEA with a prevalence between 0.27% and 1%. It most commonly presents as a pseudoaneurysm, draining sinus or neck swelling. The highest incidence is during the first year after the operation, and especially within the first three months postop due to contamination or wound infections; however, late presentations such as our case are rare. Bacterial cultures are positive in around 80% of the cases, growing mostly gram-positive cocci. Other organisms include *Pseudomonas* and *Enterobacter*. Management of CPI is challenging; difficulties include distal ICA control, friable arteries and adhesions to cranial nerves. Debridement with ligation of the vessel stump is an option, but may not be tolerated. Best outcomes are obtained with autogenous revascularization after debridement as was done in our case on the right side. Newer endovascular techniques may provide alternatives in urgent or high-risk situations, especially as staged procedures. This case is unique in its bilaterality and the longest time till presentation in the literature.

Despite advances in carotid stenting, carotid endarterectomy (CEA) remains the most widely performed procedure for moderate to severe carotid

stenosis. Closure of the arteriotomy is done in different ways including primary closure, eversion, endarterectomy and patch repair. The latter can be

*Declaration of Interests: None.*

*Division of Vascular and Endovascular Surgery, Department of Surgery, American University of Beirut Medical Centre, Hamra, Beirut, Lebanon.*

*Correspondence to: Fady Haddad, MD, Division of Vascular and Endovascular Surgery, Department of Surgery, American University*

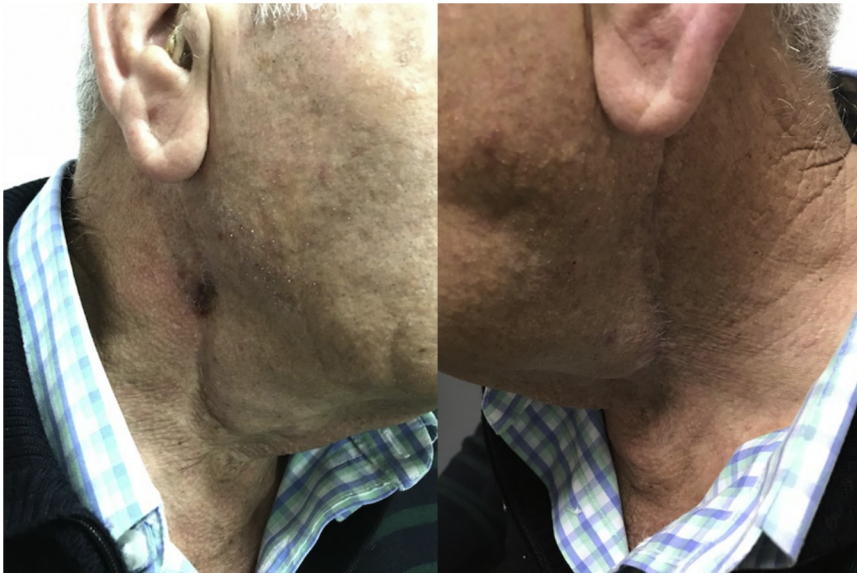*of Beirut Medical Center, Cairo street, Hamra, Beirut, Lebanon; E-mail: fh16@aub.edu.lb*

*Ann Vasc Surg 2020; 65: 285.e11–285.e15*

*<https://doi.org/10.1016/j.avsg.2019.11.005>*

*© 2019 Elsevier Inc. All rights reserved.*

*Manuscript received: August 10, 2019; manuscript accepted: November 1, 2019; published online: 6 November 2019*



**Fig. 1.** Right neck draining sinus and left scar of previous surgeries.

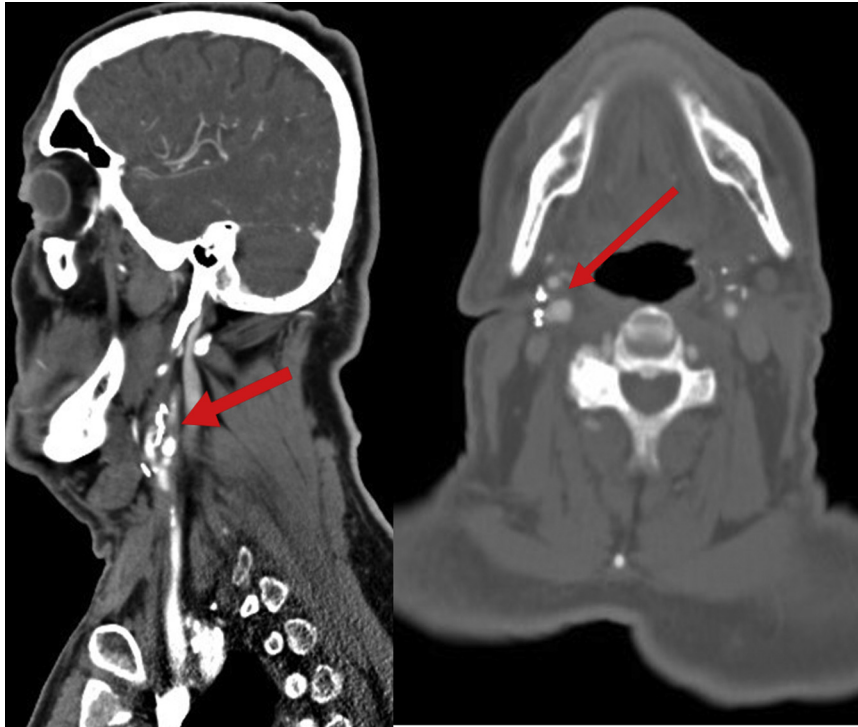
done with vein, prosthetic or biologic material. Outcomes related specifically to types of closure showed some lower rate of late restenosis with eversion (eCEA) versus conventional endarterectomy (cCEA).<sup>1</sup> However using patch closure with cCEA was found to be superior to both cCEA with primary closure and eCEA in long-term outcomes.<sup>1–3</sup> Prosthetic patch infection remains a dreaded complication of patch closure.<sup>2</sup> It presents as a swelling, a draining sinus or a pseudoaneurysm, and it occurs in 0.27% to 1% of cases.<sup>2,4</sup> We are sharing a case of carotid patch infection occurring 12 years after implantation, the implications, alternative, contemporary management options and literature update.

## CASE

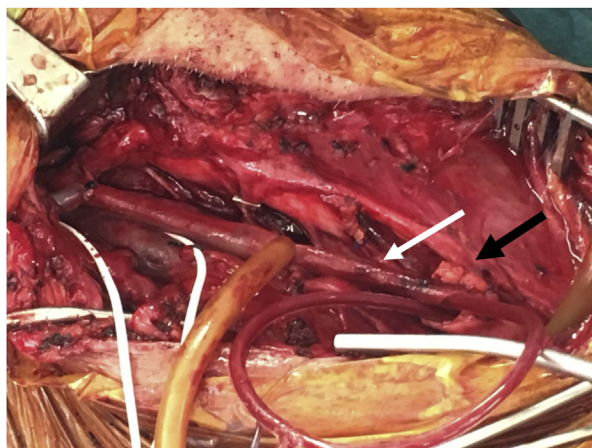
Patient is 76 y-old male, smoker, nondiabetic, known to have coronary artery disease with history of bilateral CEA 12 years prior to presentation with Dacron patch material. Procedure reported as uneventful with no perioperative infections or hematomas. He was operated a year ago at another institution for left neck draining sinus. This procedure resulted following patch excision and control of bleed, in ICA ligation. Patient suffered hoarseness and swallowing difficulty. Both slowly improved over time, with mild residual deficits. Few months later he presented with right neck draining sinus (Fig. 1) treated repeatedly with antibiotics. CT scan confirmed the presence of sinus tract reaching the carotid sheath. Irregular patch material was

described with no evidence of pseudoaneurysm (Fig. 2). The patient had no history of recent infections or dental procedures, and a preoperative echocardiogram was done showing a calcified aortic valve with severe stenosis but no evidence of vegetations or infections. Surgery was performed under EEG and NIRS oximetry. Vagus nerve identified and common carotid controlled; XII and IX nerves dissected, but were densely scarred and adherent to the upper edge of the patch. Distal ICA transected just above the end of the patch, shunting was done (Pruitt-Inahara) between the CCA and the distal ICA (Fig. 3). The patch and remaining ICA were excised; the stump of the external carotid was oversewn. Reversed GSV graft was mounted over the shunt and a CCA to distal ICA bypass was constructed starting with distal anastomosis (Fig. 4). No perioperative strokes were noted and the vocal cords were intact. Patient had early postoperative swallowing difficulties, likely related to glossopharyngeal palsy (IX); he was counseled by our speech therapy service, but refused temporary nasogastric feeding. He progressively improved and symptoms resolved over a six-wk period. Intraoperative culture of the patch grew *Staphylococcus* species coagulase negative, heavy growth in two specimens. Patient was discharged on linezolid and ciprofloxacin for one month.

At one-year follow-up patient was doing well; duplex control showed moderate proximal anastomosis stenosis; he had interval uneventful TAVR procedure.



**Fig. 2.** CT scan preoperative (sagittal and axial views). Red arrow: patched area and crimped patch material.



**Fig. 3.** Intraoperative image, shunt in place (black arrow: CCA stump, white arrow: vein bypass over the shunt).

## DISCUSSION

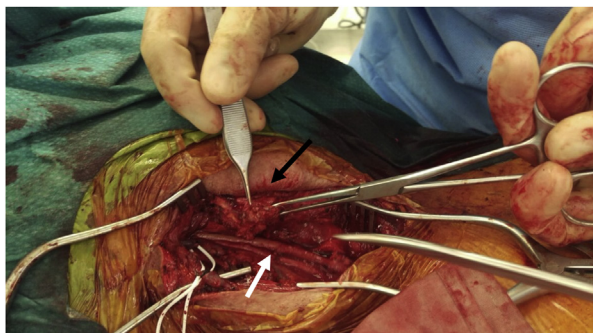
### Prevalence

Carotid patch infection is a well-documented complication following CEA.<sup>4–6</sup> A comprehensive review on Dacron Patch infection in CEA Knight and Tait from Manchester in 2008 counted 77 such cases in the literature with a prevalence of 0.25% to 0.5%.<sup>6</sup> This is significant considering the number of patch closures used today,

especially with evidence available confirming higher restenosis and complications after primary closures.<sup>1,3</sup> Later in 2012, the Leicester group reported 123 cases including their own series of 22, which was the largest in the literature.<sup>7</sup> The prevalence in this series was 0.85%. Up to this date and including the current report we could count 132 cases in the literature. Currently, many prefer prosthetic patch or bioprosthetic material for the ease and availability of those, in addition to saving the vein. In one of the largest series from Italy reporting on 8,743 CEA cases patch closure was used in 17.5%. In cases of patch infection (13 patients, 0.85%), the patch was removed and replaced with a saphenous vein. In all cases, except one fatal stroke, recovery was uneventful.<sup>8</sup> There are no risk factors directly associated with carotid patch infection in literature because of its low incidence. However, since it is strongly associated with surgical site infections, conditions like perioperative hematomas, diabetes and immunosuppression may increase the risk for its incidence.<sup>4</sup>

### Presentation

Pseudoaneurysm formation seems to be one of the most common presentations (in around a third of



**Fig. 4.** Bypass completion (black arrow: crimped patch material and sinus tract, white arrow: CCA to ICA vein bypass).

the patients), followed closely by draining sinus, as per our case, and neck swelling.<sup>6</sup> An early report by Branch and Davis linked infection and pseudoaneurysm formation after CEA, with an incidence of 0.3% after patch repairs.<sup>9</sup> One of the largest series of prosthetic patch infections, 13 cases of patch infections associated with pseudoaneurysms were described by Cooley's group; they highlighted the importance of urgent repair and the use of autogenous material.<sup>10</sup> Though in the 22 cases reported by Mann et al.,<sup>7</sup> sinus drainage seemed slightly more prevalent (41%), there may be an association between the times of presentation where by the longer that interval the more likely to present with sinus drainage versus other presentations like local infection, sepsis and stroke.<sup>4,6</sup> The bilateral occurrence by itself is an uncommon event, described only once by Knight and Tait in the literature.<sup>6</sup>

The investigational test of choice would be initially Duplex ultrasonography, which is safe, cost-effective, helps detecting fluid around the graft and very highly sensitive for pseudoaneurysms. Also corrugation and irregularities along the patch may be early signs of infection. In our case the patient presented already with draining sinus, the history from the contralateral side and a CT already done on presentation.<sup>6</sup>

### Timing

Time to presentation varies, but historically most occur during the first year; half within the first three months largely related to postoperative wound infection or contamination with highly virulent organisms. This corroborated the findings of Naylor and his co-authors from the UK,<sup>5</sup> where by four-fifths of patch infection occurring in the first 90 days in their own series were preceded with wound infection. Our patient's presentation

12 years following his bilateral carotid operation is unique, since it is by far the longest reported in the literature. There are two late presentations that could be tracked; the first was reported recently in 2017 by Xu and his colleagues from Perth, Australia,<sup>11</sup> with four years to presentation; and the second is part of the series from Mann et al. from the Royal infirmary, Leicester group, presenting after 130 months with false aneurysm; however, there were no bacteriologic proof of infection in this case.<sup>7</sup>

### Bacteriology

In 78% of cases where a bacteriology was included, the culture was positive<sup>7</sup>; among those, 91% reported gram-positive cocci (mostly *Staphylococcus aureus* and *Staphylococcus epidermidis*; some strains of MRSA in the more recent cases)<sup>6,7</sup>; the remaining include *Enterobacter*, *Pseudomonas*, *Bacteroides*, *Proteus*, *Coliform*, *Enterococcus* and *Corynebacterium*. Seven of the eight cases reported by Naylor et al.<sup>5</sup> cultured gram-positive (6 staphylococcus and 1 streptococcus) with the remaining one being pseudomonas.

In our case, there were two cultures (from the right side), *E. coli* originated preoperatively from the sinus tract drainage, and the second was the final intraoperative culture, which grew *Staphylococcus* species, heavy growth in two specimens. The former could possibly have been sinus exit tract contamination.

### Management

Cases of carotid patch infection are uniformly reported as challenging and high-risk; some of the issues are related to the difficulty in getting distal control on the ICA, especially in friable arteries with *Staphylococcus* infections. Adhesions to the cranial nerves namely the hypoglossal and glossopharyngeal are also a challenge. Elevated numbers of peripheral cranial nerve deficit during those cases are reported, up to 41%.<sup>7</sup> Debridement-only with ligation of the vessel stump seems an attracting option; however, large number of patients would not tolerate it (around 50% in the literature). Using cerebral monitoring like TCD or EEG may help in those situations. This was objectively looked at in the cases reported by Naylor and his colleagues using TCD monitoring.<sup>5</sup> Our patient already had the contralateral side ligated. EEG monitoring and shunting were used in the subsequent procedure. Reconstructing with prosthetic material again leads to unacceptably elevated reinfection rate in cases where follow-up is documented and thus is not

recommended.<sup>5,7</sup> In the series reported by El-Sabrou et al.<sup>10</sup> about 13 prosthetic patch infections with pseudoaneurysms, four-sixths treated with prosthetic material had major complications, between patch reinfection and death. On the contrary, in the large CEA series from Chelsea<sup>8</sup> with 13 cases of assumed prosthetic patch infection replaced with vein graft, none had recurrent infection, and only one death from major stroke. Overall, best outcomes reported are when reconstruction is made with autogenous material (vein patch or vein bypass) after debridement of the affected vessel wall. There is little data about the use of bovine patches in the repair of infected carotid patches, but since bovine patches seem to be safe and durable to use in the repair of other infected arterial grafts, they can be considered as an alternative if autologous grafts could not be harvested.<sup>12</sup> In our case, reversed vein bypass from the CCA to the distal ICA over a shunt was done (Fig. 3), along with excision of all prosthetic material. Other contemporary options as well, using the benefit of endovascular assisted techniques, offer the possibility of covered stenting, followed by surgical excision of patch material. This may avoid hazards of proximal control in high patch ICA junctions<sup>11</sup> and the extensive dissection possibly increasing the risk of peripheral nerve injury. However, putting covered stent in an infected field has its own possible complications, which would be very complex to treat.

## SUMMARY

Carotid Dacron patch infection is rather a rare occurrence; yet not a negligible one, with prevalence averaging 0.5% and possibly underreported. Treatment is complex and carries higher risk of nerve injuries and strokes than the original operation. Debridement of all prosthetic material and repair with autogenous tissue gives the best outcome. Emerging endovascular options, possibly as a staged approach, may play a role in urgent cases

or difficult anatomy. This case here is unique in its bilaterality, as well as its time for presentation 12 years after the index operations. Vigilant follow-up of such cases overtime is important, in addition to considering other patch material like bioprosthetic or autogenous when indicated.

## REFERENCES

1. Rerkasem K, Rothwell PM. Systematic review of randomized controlled trials of patch Angioplasty versus primary closure and different types of patch materials during carotid endarterectomy. *Asian J Surg* 2011;34:32–40.
2. Paraskevas K, Roberston V, Saratzis AN, et al. An updated systematic review and meta-analysis of outcomes following eversion vs. conventional carotid endarterectomy in randomized controlled trials and Observational Studies. *Eur J Vasc Endovasc Surg* 2018;55:465–73.
3. Ren S, Li X, Wen J, et al. Systematic review of randomized controlled trials of different types of patch materials during carotid endarterectomy. *PLoS One* 2013;8:e55050.
4. Krishnan S, Clowes AW. Dacron patch infection after carotid endarterectomy: case report and review of the literature. *Ann Vasc Surg* 2006;20:672–7.
5. Naylor AR, Payne D, London NJ, et al. Prosthetic patch infection after carotid endarterectomy. *Eur J Vasc Endovasc Surg* 2002;23:11–6.
6. Knight BC, Tait WF. Dacron patch infection following carotid endarterectomy. *Eur J Vasc Endovasc Surg* 2009;37:140–8.
7. Mann CD, McCarthy M, Nasim A, et al. Management and outcome of prosthetic graft infection after CE: a single-center series and systemic review of the literature. *Eur J Vasc Endovasc Surg* 2012;44:20–6.
8. Chiesa R, Melissano G, Castellano R, et al. Carotid endarterectomy: experience in 8743 cases. *HSR Proc Intensive Care Cardiovasc Anesth* 2009;1:33.
9. Branch CL Jr, Davis CH Jr. False aneurysm complicating carotid endarterectomy. *Neurosurgery* 1986;19:421–5.
10. El-Sabrou R, Reul G, Cooley DA. Infected post-CEA pseudoaneurysms: retrospective review of a series. *Ann Vasc Surg* 2000;14:239–47.
11. Xu JH, Altaf N, Tosenovsky P, et al. Management challenges of late presentation Dacron patch infection after carotid endarterectomy. *BMJ Case Rep* 2017;221541.
12. McMillan WD, Leville CD, Hile CN. Bovine pericardial patch repair in infected fields. *J Vasc Surg* 2012;55:1712–5.