Check for updates

Received: 19 April 2020 | Revised: 26 October 2020 | Accepted: 6 November 2020

DOI: 10.1111/ajt.16399

CASE REPORT

AJT

Collagenofibrotic glomerulopathy in a kidney transplant recipient: A first report

Sara S. Jdiaa[1] | Gilbert W. Moeckel[2] | Hala M. Kfoury[3] | Walid A. Medawar[1] | Ali K. Abu-Alfa[1,4]

[1]Division of Nephrology and Hypertension, Department of Internal Medicine, Faculty of Medicine, American University of Beirut, Beirut, Lebanon

[2]Division of Renal Pathology and Electron Microscopy, Department of Pathology, Yale University School of Medicine, New Haven, Connecticut

[3]Division of Anatomic Pathology, Department of Pathology and Laboratory Medicine, Faculty of Medicine, American University of Beirut, Beirut, Lebanon

[4]Section of Nephrology, Department of Internal Medicine, Yale University School of Medicine, New Haven, Connecticut

Correspondence
Ali K. Abu-Alfa, Division of Nephrology and Hypertension, Department of Internal Medicine, American University of Beirut Faculty of Medicine, Beirut, Lebanon.
Email: abualfa@aub.edu.lb

Abstract

Collagenofibrotic glomerulopathy (CG) is a rare disease characterized by the deposition of collagen type 3 fibrils in the glomeruli. Patients may have proteinuria, hematuria, and/or renal dysfunction. CG is considered a progressive disease with variable rates of progression. The definitive diagnosis is made by electron microscopy with the presence of characteristic subendothelial and mesangial curved, comma-like, banded collagen type 3 fibers of 40–65 nm periodicity. We are reporting the first case of CG in a kidney transplant recipient with kidney disease of unknown cause.

KEYWORDS
clinical research/practice, genetics, kidney transplantation/nephrology, recurrent disease

1 | INTRODUCTION

Type 3 collagen (COL3) is a triple helix protein composed of identical alpha-1 (III) chains.[1] COL3 is produced from its precursor, type III Procollagen Peptide (PIIINP), after the enzymatic cleavage of the N-terminal peptide.[2] In normal kidneys, COL3 is found in the interstitium and blood vessels but not in the glomeruli.[3,4] The detection of COL3 fibers in the glomeruli can be seen in the context of glomerular lesions related to sclerosis such as diabetic glomerulosclerosis and other nephropathies.[5] In the rare entity of collagenofibrotic glomerulopathy (CG) excess atypical curled COL3 are seen on ultrastructural examination, whereas these fibers are straight in the aforementioned entities.[6,7] Herein, we are describing a first case of CG in a transplant recipient.

Abbreviations: CG, collagenofibrotic glomerulopathy; COL3, type 3 collagen; PIIINP, type III procollagen.

2 | CASE REPORT

A 39-year-old Iraqi man with a living-related kidney transplant presented to the nephrology clinic at our center in 2014 for the evaluation of worsening allograft function over the past year. He was recognized to have CKD5 at the age of 26 after the development of significant periorbital and lower extremities edema. The cause of his kidney disease remained unknown as a biopsy was not performed. He has a negative family history for kidney disease. In 2001, the patient had a pre-emptive transplant from his sister aged 37 at the time. She was not known to have any kidney issue at the time of donation although no laboratory tests could be made available for review as the transplant and care took place long time ago at a medical center in Iraq.

© 2020 The American Society of Transplantation and the American Society of Transplant Surgeons

The patient was diagnosed with hypertension and diabetes mellitus 3 years prior to presentation. Prior to this recent deterioration in kidney function, his serum creatinine had been stable at around 1.2 mg/dl for 12 years. He was maintained on cyclosporine, azathioprine, and prednisone till this past year when the regimen was changed to tacrolimus, mycophenolate mofetil (MMF), and prednisone.

Of note, the donor had since developed diabetes and hypertension, recognized 7 and 14 years post-donation, respectively. The only made available laboratory reports are from 15 years later starting in 2016 and included normal creatinine readings of 0.8–1.0 mg/dl (last being in 2018), significantly elevated HbA1C values in the 9.0%–11.5% range and serial urinalyses showing glycosuria, proteinuria, and microscopic hematuria. Creatinine started rising to reach 1.4 mg/dl about 18 years post-donation in 2019.

An allograft biopsy was performed for persistently elevated creatinine of 2.2 mg/dl as well as 1.2 g of proteinuria and 0.6 g of albuminuria per 24 h. Other laboratory findings included the absence of hematuria on urinalysis, tacrolimus level of 4.6 ng/ml, HbA1c of 7.8%, and negative HIV, hepatitis B, hepatitis C serological tests. The kidney biopsy consisted of renal cortex (70%) and medulla (30%). On light microscopy, 32 glomeruli were identified, 7 of which were globally sclerotic. The preserved glomeruli showed a membrano-proliferative pattern of injury with endocapillary hypercellularity, thickened glomerular capillary wall, and focal double contour formation in a number of glomeruli. Mesangial matrix expansion and hypercellularity were noted with thickened capillary walls (Figure 1A–C). Interstitial fibrosis with proportional tubular atrophy involving 40% of the biopsy was noted on the trichrome stain. The tubules showed focal acute tubular injury with cytoplasmic vacuolization of the epithelial cell cytoplasm. There was focal interstitial infiltrate consisting of lymphocytes and plasma cells, predominantly in the scarred areas. The arterioles and arteries showed nodular hyalinosis and intimal sclerosis, respectively. Immunofluorescence (IF) was negative for IgA, IgG, IgM, C3, C4, C1q, kappa, and lambda. Immunohistochemistry (IHC) stain for collagen III was positive in segmental areas of the mesangium and in sections of the capillary loops (Figure 2). IHC stain for collagen IV was strongly positive along the capillary walls and to a much lesser degree in the mesangial areas (Figure 3).

Electron microscopy (EM) study revealed significant glomerular changes. The capillary loops were patent. There was accumulation of collagen fibers between the capillary basement membranes and endothelial cells (Figure 4). The endothelial cells were swollen. The mesangium showed increase in matrix deposition with accumulation of collagen fibers. On high power view the collagen fibers showed typical periodicity (Figure 5). The GBM showed segmental mild increase in thickness (mean 450 nm) with global foot process effacement seen. The mesangial collagen fibrils were globally present in several mesangial regions by EM examinations. The tubules showed tubular injury with cytoplasmic vacuolization. No subepithelial, subendothelial, or mesangial electron dense deposits were identified.

The allograft pathology findings were consistent with the diagnosis of collagenofibrotic glomerulopathy (CG) with evidence of calcineurin inhibitor toxicity. Since there is no proven treatment for CG, same immunosuppressive regimen was continued and angiotensin-converting enzyme inhibitor was added. Follow-up after the biopsy was notable for a progressive rise in serum creatinine reaching 3 mg/dl at 5 years.

3 | DISCUSSION

Collagenofibrotic glomerulopathy, also known as primary glomerular fibrosis and collagen type III glomerulopathy, is a rare form of glomerular disease with less than 50 reported cases in the literature.[3,5] CG belongs to the category of non-amyloid non-immunoglobulin-derived, organized deposits.[2] Other diseases in this category are

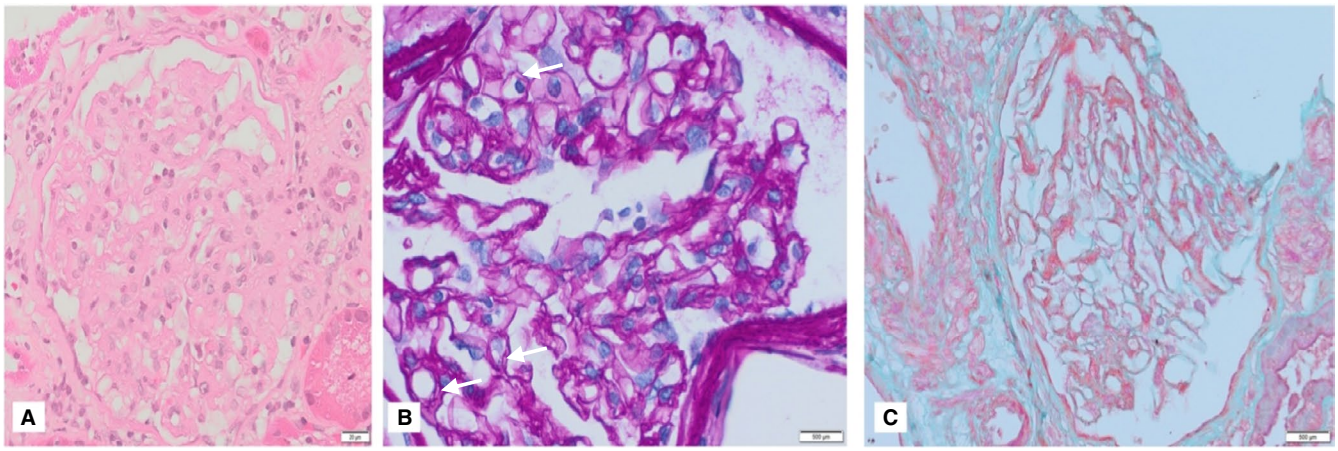

FIGURE 1 Kidney biopsy, light microscopy. (A) Photomicrograph showing endocapillary hypercellularity, thickened glomerular capillary wall, focal double contour formation, mesangial matrix expansion, and hypercellularity (H&E ×400). (B) Photomicrograph showing thick capillary walls, "double contour" formation (white arrows) and endocapillary hypercellularity. (PAS ×400). (C) Photomicrograph highlighting the periglomerular fibrosis and focal scarring in the mesangium (Masson Trichrome stain ×400) [Color figure can be viewed at wileyonlinelibrary.com]

16006143, 2021, 5, Downloaded from https://onlinelibrary.wiley.com/doi/10.1111/ajt.16399 by HINARI-LEBANON, Wiley Online Library on [19/04/2024]. See the Terms and Conditions (https://onlinelibrary.wiley.com/terms-and-conditions) on Wiley Online Library for rules of use; OA articles are governed by the applicable Creative Commons License

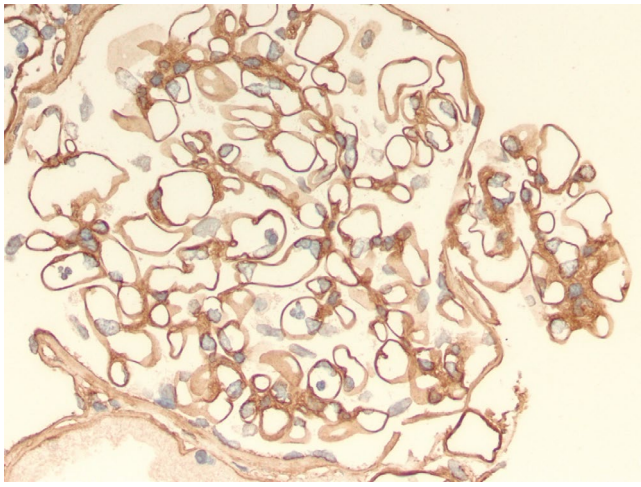

FIGURE 2 Positive immunostaining for Collagen Type III in the mesangium and along the glomerular capillary walls (×400) [Color figure can be viewed at wileyonlinelibrary.com]

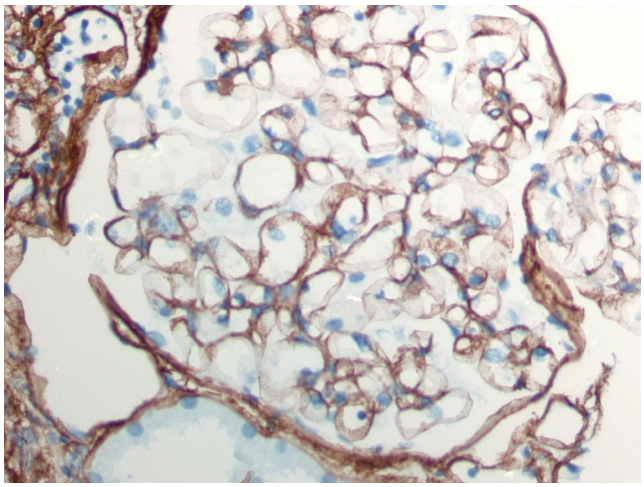

FIGURE 3 Collagen Type IV immunostaining shows strong positivity along the glomerular capillary walls and to a much lesser degree in the mesangial areas (×400) [Color figure can be viewed at wileyonlinelibrary.com]

fibronectin glomerulopathy and diabetic sclerosis.[2] CG is characterized by excessive deposition of atypical COL3 in the glomeruli.[7,8] These unique curled and banded COL3 fibers deposit abundantly in the subendothelial and mesangial spaces.[9]

CG affects both males and females with no gender predominance.[10] It has been reported in all age groups and in different ethnicities.[3,5] CG is considered a sporadic disease.[9] However, an autosomal recessive type of inheritance affecting some families has been reported predominantly in the pediatric population.[4,10]

CG manifests as proteinuria ranging from moderately increased albuminuria to the nephrotic range, uncontrolled blood pressure, hematuria and/or decreased GFR with variable rates of progression to ESKD.[5,10,11] The absence of skeletal involvement helps in differentiating CG from nail-patella syndrome (NPS).[9,11,12] The key differences between CG and NPS are detailed in Table 1.

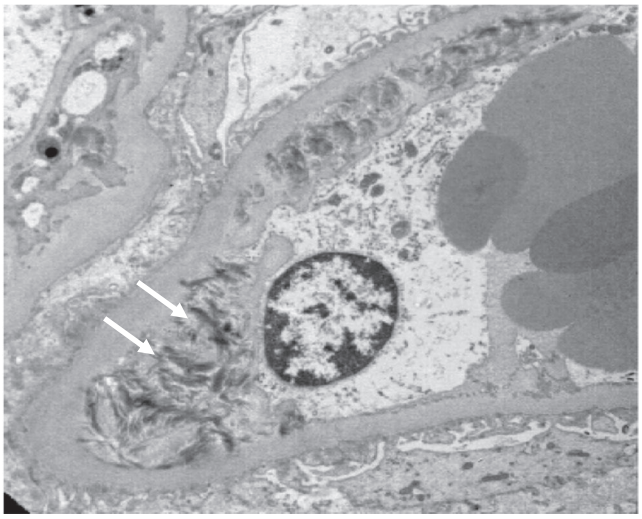

FIGURE 4 Electron microscopy showing accumulation of curved collagen fibers in the subendothelial area (white arrows) (uranyl acetate and lead citrate 12 000×) [Color figure can be viewed at wileyonlinelibrary.com]

The precise pathophysiology of CG remains uncertain.[3] Two theories have been proposed to explain this uncommon disease. One postulated that CG is an intrinsic primary renal disease resulting from an increase synthesis of atypical COL3 by activated mesangial cells.[2] This is supported by the ability of cultured mesangial cells to produce COL3 in vitro.[13] The other hypothesis considered CG a systemic disease, using the following four arguments to support this notion. First, there is an observed marked elevation in serum level of COL3 precursor, PIIINP in CG.[3] Second, there was widespread COL3 deposition at autopsy in several organs (kidneys, liver, spleen, myocardium, and thyroid) in an ESKD patient maintained on peritoneal dialysis.[6] Third, there is a reported association of CG with a number of extra-renal involvements such as factor H deficiency, hemolytic uremic syndrome, Hodgkin's lymphoma, respiratory disease, and hepatic perisinusoidal fibrosis with deposition of COL3 in these perisinusoidal areas.[3,4,11,14] Finally, the accumulation of COL3 in the subendothelial space suggested a systemic origin of these fibers.

There are three possibilities for the origin of collagen fibers in our patient, namely either a de-novo deposition of COL3 in the allograft, a recurrence of a primary disease process or a late manifestation of donor-transmitted CG in the transplanted kidney.

Except for the very elevated PIIINP level at about 10–100 times the normal range, all other laboratory findings in CG are nonspecific.[3,9] This high PIIINP is considered to be significantly elevated as levels in CKD patients do not exceed twice the normal value.[2] However, the diagnostic and prognostic values of PIIINP level in CG require further investigation. The level could not be measured in our patient.

As in many other glomerular diseases, the definitive diagnosis is based solely on the ultrastructural findings.[8] On light microscopy, CG has a membrano-proliferative pattern of injury with lobulation, endocapillary hypercellularity, and basement membrane double contouring.[7,14] The glomerular tuft is usually enlarged.[15] The mesangium shows expanded matrix with or without mild hypercellularity.[9]

16006143, 2021, 5, Downloaded from https://onlinelibrary.wiley.com/doi/10.1111/ajt.16399 by HINARI-LEBANON, Wiley Online Library on [19/04/2024]. See the Terms and Conditions (https://onlinelibrary.wiley.com/terms-and-conditions) on Wiley Online Library for rules of use; OA articles are governed by the applicable Creative Commons License

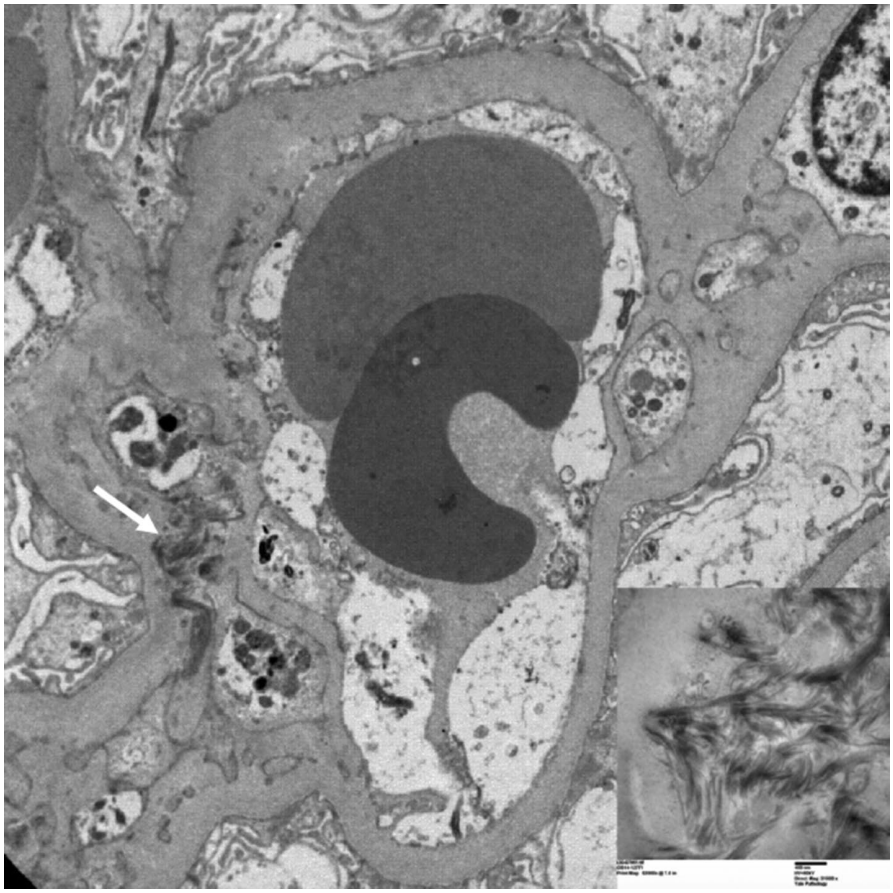

FIGURE 5 Electron photomicrograph showing accumulation of curved collagen fibers in the mesangium (white arrow). Inset: A higher magnification of the fibrils, uranyl acetate, lead citrate (×52 000) [Color figure can be viewed at wileyonlinelibrary.com]

TABLE 1 Comparative characteristics of collagenofibrotic glomerulopathy and Nail-Patella syndrome

	Collagenofibrotic glomerulopathy	Nail-Patella syndrome
First reported	1979 by Arakawa et al[17]	1934 by Aschner et al[18]
Type of inheritance	Sporadic mainly, some familial cases with autosomal recessive type of inheritance	Autosomal dominant
Pathophysiology	Still unknown	Genetic mutation in LMX1B (LMX1B is a transcription factor essential for limb, renal, and ocular development)
Renal manifestation	Proteinuria, hematuria, and/or renal insufficiency	Proteinuria, hematuria, and/or renal insufficiency
Skeletal abnormalities	Absent	Present
Site of abnormal collagen accumulation	Mesangium and subendothelial space	Lamina densa of the glomerular basement membrane (electron lucent deposits giving moth-eaten appearance by EM)
Other terminologies	Collagen type III glomerulopathy and primary glomerular fibrosis	Hereditary osteo-onychodysplasia (HOOD syndrome)

The degrees of interstitial fibrosis and tubular atrophy are variable and consistent with the extent of glomerular injury.[2,10] In advanced cases, CG can present as nodular glomerulosclerosis similar to diabetic glomerulosclerosis, monoclonal immunoglobulin deposition disease, amyloidosis, fibrillary, fibronectin, or immunotactoid glomerulopathy.[2,10] The collagen fibers in CG stain weakly on periodic acid-Schiff (PAS), positive with aniline blue and acid fuchsin orange G, and negative with Thioflavin T and Congo red.[2,3,7] IF is usually negative for complements, immunoglobulins, and light chains.[14] Some reports described nonspecific weak staining for IgM, C3, and IgG.[15] Immunohistochemistry using anti-collagen type III monoclonal antibodies confirms COL3 fibers deposition in the mesangium and the sub-endothelial space.[2,7] EM is essential in making the definitive diagnosis of CG as it helps reveal the distinctive ultrastructural characteristic of these COL3 fibers.[8] The atypical, banded, electron dense fibers are usually described as being whorled, comma-like,

16096143, 2021, 5, Downloaded from https://onlinelibrary.wiley.com/doi/10.1111/ajt.16399 by HINARI-LEBANON, Wiley Online Library on [19/04/2024]. See the Terms and Conditions (https://onlinelibrary.wiley.com/terms-and-conditions) on Wiley Online Library for rules of use; OA articles are governed by the applicable Creative Commons License

and frayed with periodicity of 40–65 nm.[8,10] They are randomly arranged in the mesangium and the subendothelial space forming irregular bundles.[3,10] They are best visualized with phosphotungstic acid or tannic acid staining rather than the regular staining by lead citrate and uranyl acetate.[4,9] Typically, there are no electron dense deposits.[9]

Up till now, no specific treatment is available for CG.[3] Performing studies to improve the renal outcome in CG patients is a very challenging task given the rarity of this disease. In addition to the standard measures to manage proteinuria, edema, anemia, and blood pressure, some nephrologists tried corticosteroids to slow the progression of this condition, but the renal outcomes were not promising.[8,15]

Successful renal transplantation in CG patients has been reported without evidence of disease recurrence but follow-up periods were relatively short of about 3 years.[2,16] Our case represents the first documentation of CG in a recipient 13 years post-transplantation. Disease occurrence, recurrence, or the manifestation of a donor-transmitted predilection or disease in an otherwise healthy transplanted kidney may be a late event, as suggested by our case. Proteinuria and decrease in GFR in the donor could be attributed to the development of diabetes and hypertension with poor control reported while the presence of hematuria may be of significance but a full evaluation for all causes was not done. It is thus difficult to draw a firm conclusion based on a single patient course especially given incomplete donor clinical information. It may be prudent to recommend a living-related donor biopsy when CG is a confirmed diagnosis in the recipient but in the absence of such a diagnosis, it is difficult to recommend such a donor biopsy with a negative family history and normal donor profile, short of a protocol biopsy.

Given the rarity of this disease, few pathologists and nephrologists will likely encounter a case of CG, limiting the understanding of this disease.

In conclusion, we are reporting the first case of posttransplant collagenofibrotic glomerulopathy.

This report highlights the importance of considering rare diseases as causes of allograft dysfunction in patients with unknown primary disease. The diagnosis of CG in the transplanted kidney should prompt a full assessment of recipient and donor to better delineate the pathogenesis of this disease.

DISCLOSURE

The authors of the manuscript have no conflicts of interest to disclose as described by the *American Journal of Transplantation*.

DATA AVAILABILITY STATEMENT

The data that support the findings of this study are available from the corresponding author upon reasonable request.

ORCID

Sara S. Jdiaa https://orcid.org/0000-0003-0726-7931
Gilbert W. Moeckel https://orcid.org/0000-0002-6059-0837
Ali K. Abu-Alfa https://orcid.org/0000-0001-8122-0221

REFERENCES

1. van der Rest M, Garrone R. Collagen family of proteins. *FASEB J*. 1991;5(13):2814-2823.
2. Alchi B, Nishi S, Narita I, Gejyo F. Collagenofibrotic glomerulopathy: clinicopathologic overview of a rare glomerular disease. *Am J Kidney Dis*. 2007;49(4):499-506.
3. Soni SS, Gowrishankar S, Nagarik AP, et al. Collagenofibrotic glomerulopathy in association with Hodgkin's lymphoma. *Saudi J Kidney Dis Transpl*. 2011;22(1):126-129.
4. Gubler MC, Dommergues JP, Foulard M, et al. Collagen type III glomerulopathy: a new type of hereditary nephropathy. *Pediatr Nephrol*. 1993;7(4):354-360.
5. Bao H, Chen H, Zhu X, et al. Clinical and morphological features of collagen type III glomerulopathy: a report of nine cases from a single institution. *Histopathology*. 2015;67(4):568-576.
6. Yasuda T, Imai H, Nakamoto Y, et al. Collagenofibrotic glomerulopathy: a systemic disease. *Am J Kidney Dis*. 1999;33(1):123-127.
7. Imbasciati E, Gherardi G, Morozumi K, et al. Collagen type III glomerulopathy: a new idiopathic glomerular disease. *Am J Nephrol*. 1991;11(5):422-429.
8. Duggal R, Nada R, Rayat CS, Rane SU, Sakhuja V, Joshi K. Collagenofibrotic glomerulopathy-a review. *Clin Kidney J*. 2012;5(1):7-12.
9. Cohen AH. Collagen type III glomerulopathies. *Adv Chronic Kidney Dis*. 2012;19(2):101-106.
10. Fogo A, Type III. Collagen glomerulopathy (collagenofibrotic glomerulopathy). *Am J Kidney Dis*. 2001;38(4):E15-E16.
11. Mizuiri S, Hasegawa A, Kikuchi A, Amagasaki Y, Nakamura N, Sakaguchi H. A case of collagenofibrotic glomerulopathy associated with hepatic perisinusoidal fibrosis. *Nephron*. 1993;63(2):183-187.
12. Najafian B, Smith K, Lusco MA, Alpers CE, Fogo AB. AJKD atlas of renal pathology: nail-patella syndrome-associated nephropathy. *Am J Kidney Dis*. 2017;70(4):e19-e20.
13. Scheinman JI, Tanaka H, Haralson M, Wang SL, Brown O. Specialized collagen mRNA and secreted collagens in human glomerular epithelial, mesangial, and tubular cells. *J Am Soc Nephrol*. 1992;2(10):1475-1483.
14. Vogt BA, Wyatt RJ, Burke BA, Simonton SC, Kashtan CE. Inherited factor H deficiency and collagen type III glomerulopathy. *Pediatr Nephrol*. 1995;9(1):11-15.
15. Dong J, Wei H, Han M, Guan Y, Wu Y, Li H. Collagen type III glomerulopathy: a case report and review of 20 cases. *Exp Ther Med*. 2015;10(4):1445-1449.
16. Suzuki T, Okubo S, Ikezumi Y, et al. Favorable course of collagenofibrotic glomerulopathy after kidney transplantation and questionnaire survey about the prognosis of collagenofibrotic glomerulopathy. *Nihon Jinzo Gakkai Shi*. 2004;46(4):360-364.
17. Arakawa M, Fueki H, Hirano H, et al. Idiopathic mesangio-degenerative glomerulopathy. *Jpn J Nephrol*. 1979;21:914-915.
18. Aschner B. A typical hereditary syndrome: dystrophy of the nails, congenital defect of the patella and congenital defect of the head of the radius. *J Am Med Assoc*. 1934;102(24):2017-2020.

How to cite this article: Jdiaa SS, Moeckel GW, Kfoury HM, Medawar WA, Abu-Alfa AK. Collagenofibrotic glomerulopathy in a kidney transplant recipient: A first report. *Am J Transplant*. 2021;21:1948–1952. https://doi.org/10.1111/ajt.16399

16006143, 2021, 5, Downloaded from https://onlinelibrary.wiley.com/doi/10.1111/ajt.16399 by HINARI-LEBANON, Wiley Online Library on [19/04/2024]. See the Terms and Conditions (https://onlinelibrary.wiley.com/terms-and-conditions) on Wiley Online Library for rules of use; OA articles are governed by the applicable Creative Commons License