



Case Report

Mesenteric venous thrombosis presenting as gastrointestinal bleeding, a challenging diagnosis



Iskandar Berbari, M.D., Rawan Safa, M.D., Gilbert Abou Dagher, M.D. *

Department of Emergency Medicine, American University of Beirut Medical Center, Beirut, Lebanon

ARTICLE INFO

Article history:

Received 25 October 2018

Accepted 5 November 2018

Keywords:

Mesenteric venous thrombosis
Acute mesenteric venous thrombosis
Gastrointestinal bleeding
Misdiagnosis
Computed topography
Emergency Department

ABSTRACT

Acute mesenteric venous thrombosis (MVT) is an uncommon cause of intestinal ischemia and is associated with high morbidity and mortality. Patients with acute MVT often present with gastrointestinal (GI) bleeding and other nonspecific findings making the diagnosis challenging. This condition requires emergent treatment. The high rates of misdiagnosis of these patients and subsequently the delay in proper and quick management put patients at increased risk of having a negative outcome. Physicians should suspect acute MVT in patients with GI bleed while also considering other factors such as, a past medical history of pro-thrombotic conditions, past surgical history of splenectomy, symptoms of nausea, vomiting, abdominal pain, physical exam findings of abdominal tenderness and abdominal distention and a laboratory workup indicating leukocytosis and an increased plasma lactic acid level. An increase in the yield of accurate diagnosis of acute MVT is possible if physicians in the ED accurately interpret all these findings. The authors herein present a case of acute MVT in a patient whose initial complaint was GI bleeding and provide a thorough review of the literature of cases of acute MVT presenting with GI bleed.

© 2018 Elsevier Inc. All rights reserved.

1. Introduction

Acute mesenteric venous thrombosis (MVT) is a rare and infrequent cause of intestinal ischemia and can be life-threatening [1]. Acute MVT accounts for 5–15% of all mesenteric ischemia, and 6–9% of cases of acute mesenteric ischemia [2,3]. It is responsible for 1 in 1000 of Emergency Department (ED) admissions, and 1 in 5000 to 15,000 inpatient

admissions [2]. MVT can be due to local vessel wall injury, venous stasis, or prothrombotic states [2]. The superior mesenteric vein (SMV) is more commonly involved, with inferior mesenteric vein (IMV) thrombosis being the cause in only 0% to 11% of MVT cases [2].

Patients with MVT with portal vein or SMV involvement have a 30-day mortality rate of 30%. Long-term survival of patients presenting with acute MVT is around 30 to 40% compared to at least 80% in patients with chronic MVT [4].

Primary, idiopathic MVT, accounts for 21 to 49% of cases [2,5,6]. Secondary causes that may result in MVT development, may include inflammatory bowel disease, prothrombotic states, surgery, and malignancy [7].

The most common presenting symptoms in acute MVT is abdominal pain, reported in 91% to 100% of the cases [8]. Most commonly, patients presenting with abdominal pain describe pain out of proportion to physical exam findings [3,9]. Other symptoms that patients may present with include nausea, vomiting, and melena [10]. Around 15% of patients present to the ED with hematemesis, hematochezia, or melena [9,10]. Moreover, 50% of the cases present with positive fecal occult blood test (FOBT) [9,11]. Since patients may present with vague, nonspecific clinical symptoms, this may result in a missed or delayed diagnosis [12].

Despite great advancements in imaging techniques for MVT diagnosis as well as MVT management, there is still considerable delay in diagnosis because of the nonspecific clinical presentation of patients [7]. This is a case review of patients presenting with gastrointestinal hemorrhages to the Emergency Department (ED) and who were found to

Abbreviations: /mm³, per millimeter cube; °C, Degrees Celsius; µg/min, micrograms per minute; BP, blood pressure; BUN, blood urea nitrogen; cm, centimeter; CO₂, carbon dioxide; CRE, Carbapenem resistant Enterobacteriaceae; CRP, C-reactive protein; CT, Computed Tomography; ED, Emergency Department; FFP, Fresh Frozen Plasma; fl, femtoliters; FOBT, Fecal occult blood test; g-GT, gamma-glutamyl transferase; g/dl, grams per deciliter; GFR, glomerular filtration rate; GI, gastrointestinal; h, hours; Hct, Hematocrit; Hg, Hemoglobin; HR, heart rate; ICU, intensive care unit; IMV, inferior mesenteric vein; INR, International Normalized Ratio; ITP, Idiopathic Thrombocytopenic Purpura; IU/l, international unit per liter; IV, Intravenous; l, liters; MCV, Mean Corpuscular Volume; mg/dl, milligrams per deciliter; mg/l, milligram per liter; ml, milliliters; ml/min, milliliter per minute; mm Hg, millimeter of mercury; mmol/l, millimoles per liter; MVT, mesenteric venous thrombosis; PE, Pulmonary Embolism; Plt, platelets; PMN, polymorphonuclear neutrophils; Post-op, post-operatively; PRBC, Packed Red Blood Cells; PT, Prothrombin Time; PTT, Partial Thromboplastin Time; RR, respiratory rate; RUQ, right upper quadrant; SBP, systolic blood pressure; S, seconds; SGOT, serum glutamic oxaloacetic transaminase; SGPT, serum glutamic pyruvic transaminase; SMV, superior mesenteric vein; SPSS, Statistical Package for Social Sciences; t-PA, Tissue Plasminogen Activator; TPN, Total Parenteral Nutrition; WBC, White Blood Cells.

* Corresponding author at: American University of Beirut Medical Center, P.O. Box 11-0236, Riad El-Solh, Beirut 1107 2020, Lebanon.

E-mail address: ga66@aub.edu.lb (G. Abou Dagher).

have acute mesenteric venous thrombosis after further workup. We also describe the case of a patient who presented to the ED with a primary complaint of lower gastrointestinal (GI) bleed and who was initially misdiagnosed, but later found to have MVT.

1.1. Objectives

The objective of this review is to report on a series of patients with a final diagnosis of acute mesenteric venous thrombosis who initially presented with gastrointestinal hemorrhage. It also describes the case of a patient with MVT who presented to the ED of a tertiary care medical center with a chief complaint of GI bleed.

2. Literature review and methods

A literature review of the published cases of acute mesenteric venous thrombosis presenting with gastrointestinal hemorrhage was conducted using the following databases: Medline (1996 to 2018), PubMed, Google Scholar, and Embase. The search terms included: “mesenteric venous thrombosis” or “mesenteric venous ischemia” or “mesenteric vascular occlusion” and “venous thrombosis”, and “gastrointestinal hemorrhage” or “hematochezia” or “melenas”. The search yielded 9 published papers discussing patients with acute MVT suffering from gastrointestinal hemorrhage; describing a total of 9 cases. The study selection was accomplished through two steps. First, the literature was reviewed and then all case reports that describe patients of interest were included. Afterwards, full articles were obtained for all accepted studies. Excluded articles included those that do not discuss acute MVT, those discussing cases from the pediatric population, or articles in any language other than English (Fig. 1).

Three tables summarize the published cases found in the literature review according to demographics, presentation, workup, imaging and treatment. Table 1 summarizes demographics, presenting symptoms, past medical history and past surgical history whereas Table 2 focuses on physical exam, laboratory and imaging findings. Table 3 includes initial diagnoses and final outcome. The tables serve as a quick reference for the currently available literature. All the patients described presented with gastrointestinal hemorrhage and were eventually diagnosed with acute mesenteric venous thrombosis. Table 4 provides descriptive statistics summarizing data pertaining to these patients and to the patient described in our case report.

To further describe the gathered data, the Statistical Package for Social Sciences (SPSS), version 25.0 was used. Descriptive statistics were summarized by presenting the mean and standard deviation for continuous variables (such as age) and number and percentage for categorical variables (such as gender) (Table 4).

3. Case

This is a case of a 25-year-old male patient with a history of refractory Idiopathic Thrombocytopenic Purpura (ITP) s/p laparoscopic splenectomy, 2 months prior to presentation, maintained on Cellcept (Mycophenolic acid) and Revolade (Eltrombopag). He presented to the ED with a 1-day history of abdominal pain and three episodes of bloody diarrhea. The patient described the pain as diffuse, constant and non-radiating, associated with nausea and one episode of non-bilious, non-bloody vomiting. On physical exam at presentation, the patient was pale and diaphoretic, normotensive (BP = 134/94 mm Hg), tachycardic (HR = 129 beats per minute), afebrile (T = 36 °C), had a normal respiratory rate (RR = 18 breaths per minute) and a normal oxygen saturation (97%). The abdomen was distended, soft, with RUQ tenderness on deep palpation with no guarding, rebound tenderness or rigidity. A digital rectal exam showed traces of fresh red blood per rectum.

On presentation, laboratory workup showed a lactic acid level of 2.31 mmol/l, Hg = 17.6 g/dl, Hct = 54%, MCV = 86 fl, WBC = 15,900/mm³ with 81% PMN, Plt = 131,000/mm³, Creatinine = 2.4 mg/dl (from a baseline of 0.7mg/dl), GFR = 36 ml/min, BUN = 20 mg/dl, Total bilirubin = 0.6 mg/dl, Direct bilirubin = 0.1 mg/dl, Sodium = 143 mmol/l, Potassium = 3.7 mmol/l, CO₂ = 16 mmol/l, Alkaline phosphatase = 131 IU/l, SGOT = 33 IU/l, SGPT = 59 IU/l, g-GT = 21 IU/l, CRP = 101.5 mg/l, PT = 14.2 s, PTT = 32.5 s, INR = 1.20.

CT abdomen and pelvis was done and showed findings concerning for enteritis including thickening of the wall of the jejunal loops and fat stranding in the adjacent mesentery. There was no evidence of chronic liver disease or portal hypertension.

Approximately 5 h after being admitted to our ED, the patient developed hemodynamic instability with bradycardia, tachypnea and hypotension (SBP dropped progressively to 60 mm Hg), followed by altered level of consciousness requiring intubation. An orogastric tube was inserted and yielded 800 ml of fresh blood. The patient had received 4 l of fluids up to this point with no improvement in hemodynamics and was started on Norepinephrine Intravenous (IV) drip at 8 µg/min.

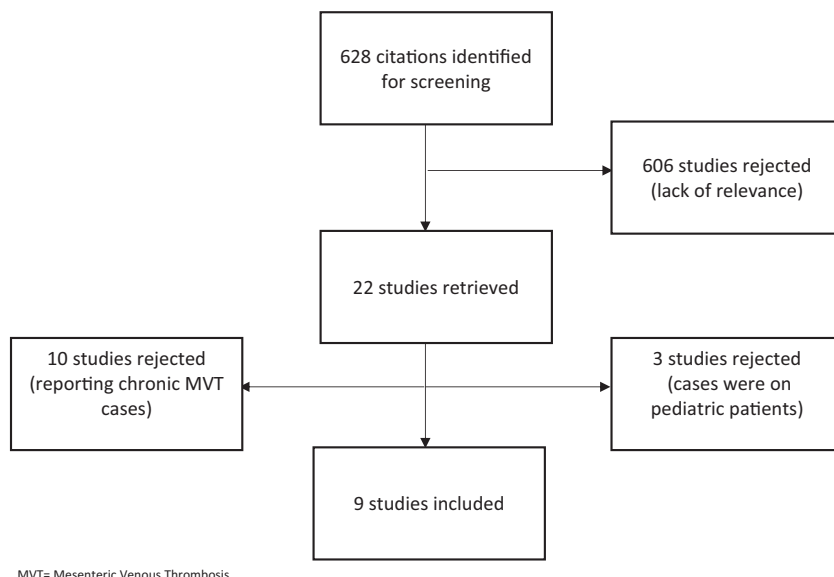


Fig. 1. CONSORT flow, study attrition diagram. MVT = Mesenteric Venous Thrombosis.

Table 1
Baseline characteristics of patients presenting to the Emergency Department.

Case	Age	Gender	Presenting symptoms	PMH	PSH	
Alhmoud et al.	[21]	31	Male	Acute upper GI bleeding	DM I, obesity	NR
Watanabe et al.	[18]	44	Male	Massive hematochezia	End stage alcoholic liver cirrhosis	NR
Murray et al.	[13]	35	Male	One-day history of crampy, sharp lower abdominal pain with no radiation, associated with nausea, vomiting, and hematochezia	Klinefelter's syndrome, Repeated venous thrombosis in his lower and upper extremities, Pulmonary Embolism	NR
Cleeves et al.	[22]	67	Female	Diffuse, worsening, colicky abdominal pain for two days, nausea worsened by eating, one day of diarrhea, and one episode of hematochezia	Cryptogenic cirrhosis and portal hypertension	NR
Katz et al.	[23]	65	Male	Melena	Gallstone pancreatitis	Cholecystectomy
Novikov et al.	[20]	65	Female	Several days of hematochezia, left lower quadrant, crampy abdominal pain	Primary biliary cirrhosis and autoimmune hepatitis	NR
Nagasue et al.	[15]	33	Female	Left-sided abdominal pain, vomiting, abdominal distension and oliguria	Esophageal varices	Splenectomy
Nicol et al.	[14]	41	Female	Acute onset of abdominal pain, nausea and vomiting with extreme focal tenderness in the right upper quadrant and epigastrium.	DMII, chronic vascular headache, seizure disorder	NR
Trenti et al.	[24]	42	Male	Severe abdominal pain and massive rectal bleeding	Chronic acquired demyelinating polyneuropathy	NR

NR: Not Reported; MVT: Mesenteric Venous Thrombosis; PMH: Past Medical History; PSH: Past surgical History; GI: Gastrointestinal; DM: Diabetes Mellitus.

Repeat labs at this time showed a drop of the hemoglobin level from 17.6 mg/dl at presentation down to 11.8 mg/dl, and platelet level decreased to 57,000/mm³. In addition, there was an increase in lactic acid to 10.33 mmol/l, creatinine increased to 3.1 with a GFR decrease to 27 ml/min, sodium increased to 150 mmol/l, potassium increased to 5.4 mmol/l and CO₂ decreased to 12 mmol/l. This rapid change in

the patient's status points to the magnitude of the GI bleed and the need for life saving interventions.

As a consequence of the patient's deterioration, the massive transfusion protocol was activated. The patient required transfusion with a total of 8 units of Packed Red Blood Cells (PRBC) (7 units given as flushes and the last one given in the ED over 1 h) given intermittently over a

Table 2
Physical exam, laboratory workup and imaging results of patients presenting to the Emergency Department.

Case	Physical exam	Laboratory workup	Imaging
Alhmoud et al.	[21] NR	INR: 1.53, Plt: 134,000/mm ³ , Hg: 5.5 mg/dl, hemorrhagic shock	CT Abdomen: superior mesenteric vein thrombosis, large hemoperitoneum (consequent to TIPS attempt), and multiple para- esophageal and perisplenic varices
Watanabe et al.	[18] NR	NR	NR
Murray et al.	[13] Febrile (38.3 °C), generalized abdominal tenderness, bowel sounds were scant, rectal examination revealed black stools that were strongly heme positive.	Hct: 38%, WBC: 14,700/mm ³ (with a left shift), Plt: 79,000/mm ³ PT: 13.8/12.4, PTT: 31/27	KUB: No acute changes. Bleeding scan: Pooling or blood in the small intestine
Cleeves et al.	[22] Scleral icterus, sublingual jaundice, abdomen diffusely tender with voluntary guarding, rectal exam revealed brown stool with streaks of red blood.	Total bilirubin: 3.2 mg/dl, direct bilirubin: 0.5 mg/dl, INR: 1.3, albumin: 3.1 g/dl, normal CBC, and normal amylase/lipases. Subsequent lactic acid analysis returned elevated at 3.2 mmol/l	CT without IV contrast: nodular, cirrhotic liver, non-specific mild ileal and colonic thickening and fat stranding. A repeat CT scan with IV contrast: revealed dilated loops of small bowel consistent with ischemic changes, right colonic luminal blood, and thrombus in the branches of the superior mesenteric vein
Katz et al.	[23] NR	NR	Magnetic resonance venography of abdomen: occlusion of the superior mesenteric vein, with numerous collateral mesenteric vessels.
Novikov et al.	[20] NR	CBC normal, lactate: 1.8 mmol/l	CT abdomen and pelvis: portal vein and superior mesenteric vein thrombosis, with proximal splenic vein thrombosis as well as hepatic vein thrombosis
Nagasue et al.	[15] Abdomen distended with palpable mass in the left abdomen, reddish brown stools, positive for occult blood	WBC: 38,600/mm ³ Plt: 170,000/mm ³	Supine and upright films of the abdomen: showed gas in the small bowel in the left side
Nicol et al.	[14] Melanotic, heme positive stool, decreased mental status, abdomen distended, tympanic with no bowel sounds	Hg: 9.2 g/dl, Plt count 177,000/mm ³ , BUN: 53 mg/dl, Creatinine: 4 g/dl, glucose: 1014 mg/dl and ketones were present.	NR
Trenti et al.	[24] NR	NR	CT scan: complete superior mesenteric and splenic vein thrombosis (VT), partial inferior vena cava and portal VT with secondary venous intestinal infarction.

NR: Not Reported; INR: International Normalized Ratio; Plt: Platelet level; Hct: Hematocrit; WBC: White Blood Cell count; PT: Prothrombin Time; PTT: Partial Thromboplastin Time; CBC: Complete Blood Count; Hg: Hemoglobin; BUN: Blood Urea Nitrogen CT: Computed Tomography; KUB: Kidney, Ureter and Bladder X-Ray; TIPS: Transjugular Intrahepatic Portosystemic Shunt.

mg/dl: milligrams per deciliter; g/dl: grams per deciliter; mmol/l: millimoles per liter; /mm³: per millimeter cube.

Table 3
Initial diagnosis and outcome of patients presenting to the Emergency Department.

Case	Initial diagnosis	Outcome
Alhmoud et al. [21]	SMVT	Alive
Watanebe et al. [18]	NR	Dead (Died before arrival to ED due massive GI bleed) Autopsy: A thrombus was observed at the terminal section of the superior mesenteric vein, that is, at the junction between the superior mesenteric vein and the splenic vein
Murray et al. [13]	SMVT	Alive
Cleeves et al. [22]	SMVT	Dead (Though she initially improved clinically, the patient later developed ventilator-associated pneumonia causing refractory shock and multi-system organ failure)
Katz et al. [23]	SMVT	Alive
Novikov et al. [20]	SMVT	Alive
Nagasue et al. [15]	Strangulation/obstruction of the small intestine	Alive
Nicol et al. [14]	Undiagnosed initially	Dead Autopsy: The entire superior mesenteric vein, splenic vein, and extra hepatic portal vein and the proximal intrahepatic portal venous system were distended with purple -gray thrombus
Trenti et al. [24]	SMVT	Alive

NR: Not Reported; MVT: Mesenteric Venous Thrombosis; SMVT: Superior Mesenteric Venous Thrombosis; ED: Emergency Department; GI: Gastrointestinal.

total of 3 h. In addition, 2 units of Fresh Frozen Plasma (FFP) and 8 units of platelets were given as boluses and IV drip respectively.

As a next step in management, an endoscopy was done which showed no active bleed but evidence of friable, violaceous and ulcerated mucosa at the proximal D3 portion of the duodenum (Fig. 2).

What followed was a repeat CT abdomen without contrast, which showed no evidence of viscus perforation but significant and extensive thickening of the jejunal loops. In addition, there was evidence of interloop fluid with small amount of free fluid in the pelvis as well as diffuse mesenteric fat stranding (Fig. 3).

In summary, the patient's clinical situation and workup were concerning for small bowel ischemia. Therefore, an emergent laparotomy was recommended, and the patient was transferred to the ICU.

Around 13 h after presenting to the ED, the patient underwent an exploratory laparotomy to rule out bowel ischemia. Exploration revealed black necrotic small bowels extending from a few centimeters beyond the ligament of Treitz and almost reaching the ileocecal valve with no evidence of perforation. The stomach, proximal duodenum and colon were healthy. The mesentery was severely congested with obviously thrombosed vessels. A decision was made to proceed with resection of the necrotic segment and further re-exploration after 24 h. The necrotic small bowel was resected and removed along with its mesentery

leaving around 7 cm from the ligament of Treitz and around 5 cm from the terminal ileum. The following day, the patient underwent a second exploratory laparotomy for duodenal drainage, ileostomy placement and appendectomy.

Post-operatively (post-op), the patient was started on Heparin intravenously and was successfully extubated on day 1 post-op. On Day 3 post-op, a CT chest angiography was done, and the patient was found to have a Pulmonary Embolism (PE). Heparin was continued and later switched to Fondaparinux in order to decrease the risk of Heparin Induced Thrombocytopenia. His course was also complicated by an *Enterobacter cloacae* Carbapenem resistant Enterobacteriaceae (CRE) infection isolated from the skin, which was treated by the placement of the patient in contact isolation and administration of the appropriate antibiotics. The patient required Total Parenteral Nutrition (TPN) throughout his post-op hospital stay.

1 month and 21 days after he initially presented to the ED, he was discharged home on TPN with a plan to schedule a small bowel transplant in the imminent future.

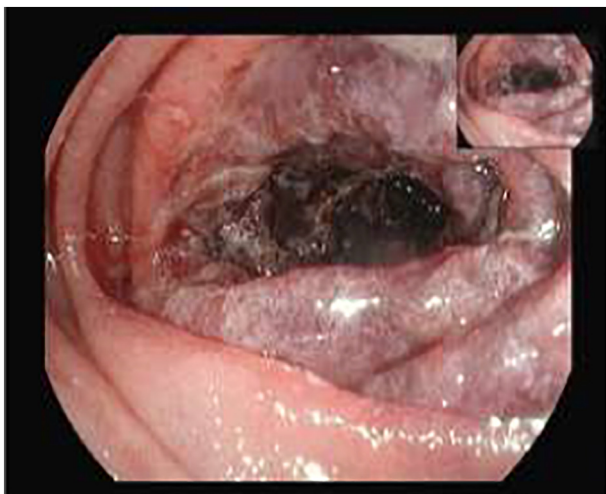


Fig. 2. Endoscopy image of proximal D3 portion of duodenum.

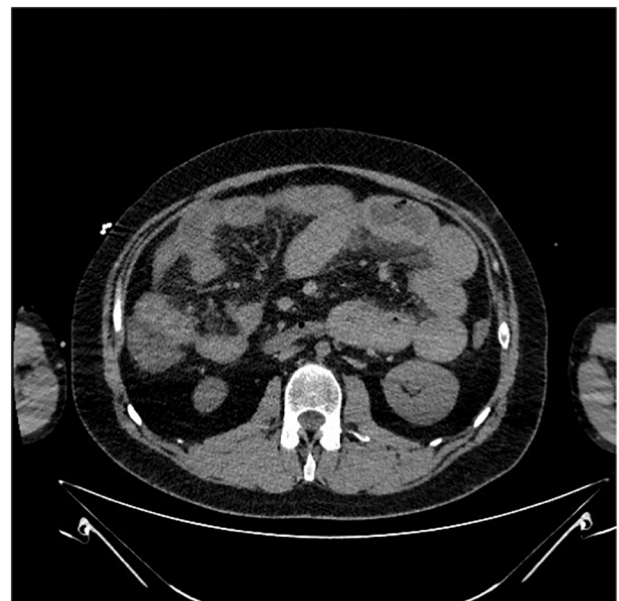

Fig. 3. CT image.

4. Discussion

Mesenteric venous thrombosis is an uncommon but potentially lethal complication of thrombotic conditions. It is notoriously difficult to diagnose prior to surgery because patients frequently present with non-specific symptoms that can possibly include obvious GI blood loss [13]. In fact, melena, hematemesis or hematochezia occur in about 15% of the cases of MVT and occult blood is present in 50% of the cases [7].

In this case series, we described the characteristics of patients who presented to the ED with GI bleed and who were found to have acute mesenteric venous thrombosis. Our goal is to better understand these patients' ED presentations in order to increase the rate of accurate initial diagnosis and management.

We reviewed 9 cases, extracted from 9 different studies, and our case report described above for a total of 10 patients. All patients included in this review suffered from acute mesenteric venous thrombosis and had GI bleeding as a presenting symptom in the ED.

Most of the patients were males (60%). The average age of the patients was 44.8 ± 15.4 5 years. All patients presented to the ED with one of the chief complaints being GI bleed: the majority had a lower GI bleed (60%), 2 patients had upper GI bleed (20%) and 2 patients were found to be occult blood positive (20%). In addition, 2 patients reported having undergone splenectomy (20%), 7 patients had abdominal pain (100%), 5 patients were complaining of nausea (71.4%), 4 patients vomited (57.1%) and only 2 patients reported diarrhea (28.6%) (Table 4).

The majority of the patients were not febrile (83.3%). On physical exam, 5 patients were found to have abdominal tenderness (83.3%) and out of these 5 patients: 2 were found to have diffuse abdominal tenderness (33.3%), 2 had findings of RUQ tenderness (33.3%) and 1 had unspecified abdominal tenderness (16.7%). Moreover, 4 patients were found to have abdominal distention (66.7%), 1 had guarding (16.7%) and none had rigidity on abdominal exam (Table 4).

Table 4
Descriptive statistics of patients with MVT.

Variables	N = 10
Age (years) mean \pm SD	44.8 \pm 15.45
Gender	
Male, n (%)	6 (60)
Female, n (%)	4(40)
Splenectomy, n (%)	2 (20)
GI Bleed, n (%)	
Lower GI bleed, n (%)	6 (60)
Upper GI bleed, n (%)	2 (20)
Occult blood positive, n (%)	2 (20)
Abdominal pain, n (%)	7 (100)
Nausea, n (%)	5 (71.4)
Vomiting, n (%)	4 (57.1)
Diarrhea, n (%)	2 (28.6)
Febrile, n (%)	1 (16.7)
Abdominal tenderness, n (%)	
Diffuse abdominal tenderness	2 (33.3)
RUQ tenderness	2 (33.3)
Unspecified	1 (16.7)
Guarding, n (%)	1 (16.7)
Abdominal distention, n (%)	4 (66.7)
White Blood Cell count (/mm ³) mean \pm SD	23,067 \pm 13,466
Hemoglobin (g/dl) mean \pm SD	10.8 \pm 6.20
Platelet (/mm ³) mean \pm SD	138,200 \pm 39,022
Lactic acid (mmol/l) mean \pm SD	2.44 \pm 0.71
Intubation, n (%)	2 (20.0)
Outcome, n (%)	
Alive at discharge	7 (70.0)
In hospital death	3 (30.0)
Missed diagnosis, n (%)	3 (33.3)

To note all percentages are reported as Valid Percentages.

MVT: Mesenteric Venous Thrombosis; SD: Standard Deviation; GI: Gastrointestinal; mg/dl: milligrams per deciliter; g/dl: grams per deciliter; mmol/l: millimoles per liter; /mm³: per millimeter cube.

As for the laboratory workup on presentation, the most pertinent findings include: an average hemoglobin level of 10.8 ± 6.2 g/dl, platelet level of $138,200 \pm 39,022$ /mm³, WBC count of $23,067 \pm 13,466$ /mm³ and a lactic acid level of 2.44 ± 0.71 mmol/l (Table 4).

In addition to patients with a known history of a prothrombotic condition, who are at increased risk of MVT [2], it seems that patients with a history of splenectomy presenting with GI bleed, nausea, vomiting, abdominal pain, with physical exam findings of abdominal tenderness and abdominal distention and with a laboratory workup indicating leukocytosis and increased lactic acid level should be investigated for MVT.

What is also striking is that 3 patients had a missed diagnosis initially (33.3%) (Table 4). More specifically, 1 patient was undiagnosed [14], 1 was incorrectly diagnosed with strangulation/obstruction of the small intestine [15] and the patient in our case report was initially thought to have enteritis.

In the literature, Divino et al. studied the characteristics of 9 patients who presented to the ER and who were eventually diagnosed with MVT. The majority of these patients (78%) had a missed initial diagnosis: 3 patients were initially diagnosed with small bowel obstruction, 2 patients with peritonitis, 1 patient with appendicitis and 1 patient with hepatitis [12].

Similarly, Sack et al. also studied the characteristic of a different set of 9 patients who were eventually found to have MVT. In that case series, 1 patient was accurately diagnosed with MVT and 3 patients had a more general diagnosis of a mesenteric vascular accident. The other 5 patients (56%) were initially misdiagnosed. Out of these 5 patients, 3 were thought to have intestinal obstruction, 1 was misdiagnosed with Crohn's disease with suspected perforation and another with intra-abdominal sepsis [16].

An explanation for this relatively high rate of missed diagnosis is that MVT has a vague clinical presentation and lacks specific diagnostic tests making early diagnosis rare [12].

In order to better understand the consequences of undiagnosed and untreated MVT, it is worth going through the pathophysiology of this condition. MVT impairs venous return from the bowel, resulting in venous engorgement and ischemia. Due to the rapid and complete occlusion of mesenteric veins, there may be insufficient time for the development of a collateral circulation and transmural bowel infarction may occur [2]. Moreover, venous engorgement may cause arterial spasm, with resulting irreversible bowel ischemia. With a transmural infarction, there is loss of integrity of the bowel mucosa, allowing bacterial translocation and potential for occurrence of the fatal consequence of lactic acidosis, sepsis, multiorgan failure, and death [2]. This emphasizes the need for physicians to accurately diagnose MVT without delay.

In our case series, 2 patients required intubation (20%) and 3 patients died in the hospital (30%). This mortality rate is similar to the one found in a systematic review conducted by shoots et al. that indicates that mean mortality rate, defined as in-hospital death, is 44% for mesenteric venous thrombosis [17] and to the one found by Oldenburg et al. who define it as ranging from 30 to 40% [4].

We have shown that patients with MVT could present with GI bleed and have high rates of misdiagnosis. The relatively high rate of initial misdiagnosis potentially delays proper and quick management. This delay could increase the rate of bowel ischemia and leads to loss of life [2]. In addition, patients with substantial GI bleed are at risk of hemodynamic instability and death as was the case for the patient described by Watanabe et al. [18] and also for the patient we described in our case report which, 5 h after being admitted to the ED, required multiple blood transfusions and urgent intubation.

Several imaging methods are available for the diagnosis of MVT [19] and CT has been shown to be the most sensitive tool for detecting acute MVT as it can establish the diagnosis in 90% of patients [5,19]. The triad of low attenuation in the SMV, thickening of the small bowel wall, and the presence of peritoneal fluid suggest that laparotomy should be performed, as bowel infarction is likely [19]. This triad mirrors the results found in the CT scans of the patients in our case series who were

accurately diagnosed with MVT following imaging (Table 2). This further supports the sensitivity of CT scans in accurately diagnosing this condition and thus avoiding delay in treatment. That being said, to be able to detect MVT using CT the physician has to have a clinical suspicion of this condition.

Finally, the treatment of mesenteric venous thrombosis involves anticoagulation alone or in combination with surgery, and it can be managed without surgery if there is no evidence of bowel infarction [10]. There are no sensitive markers to establish with certainty if a patient is at risk of bowel infarction [10]. This explains why the majority of the patients in this case series underwent exploratory laparotomy with subsequent bowel resection. The only exception was a patient who, due to multiple co-morbidities, underwent catheter-directed thrombolysis of the SMV clot with a 24-hour infusion of Tissue Plasminogen Activator (t-PA). The patient tolerated the procedure well and was discharged on Warfarin [20]. As for the post-op course of some of the other patients in our case series, one of the patients developed multiple bilateral pulmonary emboli 10 days after surgery. He was treated with intravenous Heparin and discharged to a skilled nursing facility 6 weeks later [21]. Another patient's recovery was uncomplicated, but his absorptive status was compromised, with resulting severe steatorrhea [13]. In the case described by Nagasue et al., postoperatively the patient complained of similar abdominal pain to that which she had before the operation. Accordingly, 30,000 units of Urokinase were infused during the first 3 postoperative days in order to prevent further thrombosis. She recovered gradually thereafter and was discharged 5 weeks after the operation [15].

The patient we described in our case report suffered, after his surgery, from a PE and a severe CRE infection leading to a prolonged hospital stay. Two of the patients in our case series died post-op. One of them developed ventilator-associated pneumonia causing refractory shock and multi-system organ failure, resulting in death [22]. The other, shortly after surgery, became bradycardic and pulseless and passed away despite resuscitative efforts [14].

The outcome of these patients points to the elevated mortality and morbidity of MVT and reemphasizes the need for rapid diagnosis and management of this condition.

5. Conclusion

Mesenteric venous thrombosis is a medical emergency that can affect patients of varying ages and is life-threatening if left untreated. The presenting symptoms alone lack sensitivity and it is therefore difficult to accurately diagnose this condition. High rates of misdiagnosis cause delay in proper management and place patients at risk.

Physicians should include MVT in their differential diagnosis when patients present with GI bleed while also considering other factors such as, a past medical history of pro-thrombotic conditions, past surgical history of splenectomy, symptoms of nausea, vomiting, abdominal pain, physical exam findings of abdominal tenderness and abdominal distention and a laboratory workup indicating leukocytosis and an increased plasma lactic acid level.

An increase in the yield of accurate diagnosis of MVT is possible if physicians in the ED accurately interpret all these findings. When clinical suspicion of MVT is present, a CT scan should be ordered to confirm the diagnosis and proper management should be initiated without delay.

Ethical committee approval

NA.

Competing interests

The authors have no competing interests.

Source of funding

This research did not receive any specific grant from funding agencies in the public, commercial, or not-for-profit sectors.

CRediT authorship contribution statement

Iskandar Berbari: Conceptualization, Data curation, Formal analysis, Investigation, Methodology, Visualization, Writing - original draft. **Rawan Safa:** Conceptualization, Data curation, Formal analysis, Investigation, Methodology, Visualization, Writing - original draft. **Gilbert Abou Dagher:** Conceptualization, Data curation, Formal analysis, Investigation, Methodology, Visualization, Writing - original draft.

References

- [1] Björck M, et al. Editor's choice—management of the diseases of mesenteric arteries and veins: clinical practice guidelines of the European Society of Vascular Surgery (ESVS). *Eur J Vasc Endovasc Surg* 2017;53(4):460–510.
- [2] Singal AK, Kamath PS, Tefferi A. Mesenteric venous thrombosis. *Mayo Clin Proc* 2013;88(3):285–94.
- [3] Grendell JH, Ockner RK. Mesenteric venous thrombosis. *Gastroenterology* 1982;82(2):358–72.
- [4] Oldenburg W, et al. Acute mesenteric ischemia: a clinical review. *Arch Intern Med* 2004;164(10):1054–62.
- [5] Zhang J, et al. Acute mesenteric venous thrombosis: a better outcome achieved through improved imaging techniques and a changed policy of clinical management. *Eur J Vasc Endovasc Surg* 2004;28(3):329–34.
- [6] Harnik IG, Brandt LJ. Mesenteric venous thrombosis. *Vasc Med* 2010;15(5):407–18.
- [7] Hmoud B, Singal AK, Kamath PS. Mesenteric venous thrombosis. *J Clin Exp Hepatol* 2014;4(3):257–63.
- [8] Wiersema MJ, et al. Duplex Doppler endosonography in the diagnosis of splenic vein, portal vein, and portosystemic shunt thrombosis. *Gastrointest Endosc* 1995;42(1):19–26.
- [9] Boley SJ, Kaley RN, Brandt LJ. Mesenteric venous thrombosis. *Surg Clin North Am* 1992;72(1):183–201.
- [10] Kumar S, Sarr MG, Kamath PS. Mesenteric venous thrombosis. *N Engl J Med* 2001;345(23):1683–8.
- [11] Khodadadi J, et al. Mesenteric vein thrombosis. The importance of a second-look operation. *Arch Surg* 1980;115(3):315–7.
- [12] Divino CM, et al. A retrospective study of diagnosis and management of mesenteric vein thrombosis. *Am J Surg* 2001;181(1):20–3.
- [13] Murray FE. Mesenteric vein thrombosis associated with Klinefelters syndrome—a case report. *Angiology* 1988;39(1 Pt 1):45–8.
- [14] Nicol KK, Davis GJ. An unusual complication of diabetes mellitus: the zebra that became a horse. *South Med J* 1997;90(1):83–5.
- [15] Nagasue N, et al. Mesenteric venous thrombosis occurring late after splenectomy. *Br J Surg* 1977;64(11):781–3.
- [16] Sack J, Aldrete JS. Primary mesenteric venous thrombosis. *Surg Gynecol Obstet* 1982;154(2):205–8.
- [17] Schoots IG, et al. Systematic review of survival after acute mesenteric ischaemia according to disease aetiology. *Br J Surg* 2004;91(1):17–27.
- [18] Watanabe M, et al. An autopsy case of acute massive hematochezia caused by superior mesenteric vein thrombosis: a first report in forensic medicine. *J Forensic Sci* 2016;61(1):271–3.
- [19] Bradbury MS, et al. Mesenteric venous thrombosis: diagnosis and noninvasive imaging. *Radiographics* 2002;22(3):527–41.
- [20] Novikov A, et al. Superior mesenteric vein thrombosis: to lyse or not to lyse? *American journal of gastroenterology*. 75 Varick St, 9th Flr, New York, NY 10013-1917 USA: Nature Publishing Group; 2014.
- [21] Alhmoud T, Alcorn J. It ain't always the liver: an unusual case of variceal bleeding. *American journal of gastroenterology*. 75 Varick St, 9th Flr, New York, NY 10013-1917 USA: Nature Publishing Group; 2014.
- [22] Cleaves M, et al. A case of vein pain: abdominal tenderness and diarrhea in a patient with portal hypertension. *Journal of general internal medicine*. 233 Spring St, New York, NY 10013 USA: Springer; 2010.
- [23] Katz K, et al. A rare cause of upper GI bleeding: portal hypertensive duodenopathy secondary to non-cirrhotic portal hypertension. *American journal of gastroenterology*. 75 Varick St, 9th Flr, New York, NY 10013-1917 USA: Nature Publishing Group; 2016.
- [24] Trenti C, D.A., Negri E, Galimberti D, Iori I. Iatrogenic mesenteric vein thrombosis: a case report. *Ital J Med* 2012;6(1s):141.