




Non-irradiated GCSF stimulated leukocyte transfusion for necrotizing fasciitis after allogeneic stem cell transplant: a case report and review of the literature

Nour Moukalled¹ · Imad Bou Akl² · Ahmad Al Masri³ · Zeina Kanafani⁴ · Jean EL-Cheikh ¹ · Ali Bazarbachi¹

Received: 25 July 2019 / Revised: 19 October 2019 / Accepted: 28 October 2019 / Published online: 7 November 2019
© The Author(s), under exclusive licence to Springer Nature Limited 2019

Abstract

Severe neutropenia remains among the most common complications associated with hematological diseases and their treatment, especially in the early poststem cell transplantation. Managing life-threatening infections associated with prolonged and profound neutropenia thus remains an essential component for the optimal care of patients undergoing transplant. Several therapeutic interventions have been attempted either to limit the duration of neutropenia through granulocyte colony stimulating factors (GCSF), or to treat associated infections through the use of granulocyte transfusions. The efficacy and safety of granulocyte transfusions have been controversial, and the conflicting results reported by several trials can be explained by the significant variability related to patient selection, timing of initiation, and duration of transfusions, preparation methods among multiple others. We herein report a case of life-threatening necrotizing fasciitis post haploidentical stem cell transplant, responding to the combination of antibiotics and daily transfusions of non-irradiated GCSF stimulated leukocytes from healthy donors without surgical intervention. We also provide a concise review of the available literature regarding the use of this intervention, its efficacy and safety and comparison of irradiated with non-irradiated transfusions.

Introduction

Prolonged and profound neutropenia remain among the most common factors complicating the course and management of hematological diseases, especially in the peri-transplant setting, in addition to being the most significant risk factor for morbidity/mortality in the early poststem cell transplant (SCT) period. There have been several therapeutic interventions aiming to limit the duration of neutropenia and/or decrease its severity, through the use of granulocyte colony

stimulating factor (GCSF), or to control severe infections through granulocyte transfusions from healthy donors during the period of cytopenia. We herein present a case illustrating the successful use of non-irradiated GCSF stimulated leukocyte transfusion for a patient with a life-threatening infection complicating his haploidentical SCT (haplo-SCT) for acute myeloid leukemia (AML). We will also present a concise review of the literature of the therapeutic use of granulocyte and leukocyte transfusions, including its efficacy and safety.

Case report

A 34-year-old male patient with a medical history of biopsy proven IgA nephropathy and chronic kidney disease diagnosed at the age of 30, initially treated with losartan and steroids (prednisone 20 mg/day) gradually tapered over 1 year, before achieving a stable creatinine (around 2.5 mg/dl for 2 years) while treated with mycophenolate mofetil (500 mg twice daily). He was later switched to azathioprine 50 mg three times daily for 1 year (creatinine improved to 1.6 mg/dl). In December 2018, he complained of

✉ Ali Bazarbachi
bazarbac@aub.edu.lb

¹ Bone Marrow Transplantation Program, Department of Internal Medicine, American University of Beirut, Beirut, Lebanon

² Pulmoanry and Critical Care Medicine, Department of Internal Medicine, American University of Beirut, Beirut, Lebanon

³ Department of Internal Medicine, American University of Beirut, Beirut, Lebanon

⁴ Infectious disease, Department of Internal Medicine, American University of Beirut, Beirut, Lebanon

generalized fatigue and recurrent gingival bleeding, and was found to have cytopenia (WBC $3700/\text{mm}^3$ –18% blasts, hemoglobin 9.4 g/dl, platelets $4000/\text{mm}^3$). Bone marrow evaluation confirmed AML with monocytic differentiation (36% blasts). Karyotype showed monosomy 7; molecular studies were negative for NPM1, FLT3 mutations and common AML translocations. He received induction chemotherapy with idarubicin and cytarabine (3 + 7 regimen) on December 22, 2018. Bone marrow evaluation on day 28 postinduction chemotherapy revealed complete remission with persistent monosomy 7. Because of poor performance status, he was given consolidation treatment (1 cycle of 5-azacytidine in March 2019, then 1 cycle of high dose cytarabine in April 2019). He then received conditioning with TBF protocol (Thiotepa 5 mg/kg for 1 dose, intravenous busulfan $130\text{ mg}/\text{m}^2/\text{day}$ for 2 days and fludarabine $40\text{ mg}/\text{m}^2/\text{day}$ for 4 days) with antithymocyte globulin (ATG 2.5 mg/kg) for 1 dose, as of May 9, 2019, followed by peripheral blood stem cell infusion on May 15, 2019 from his haploidentical brother, with posttransplant cyclophosphamide on days +3 and +5. His initial hospital stay was smooth (had diarrhea and mild decrease in oral intake, received total parenteral nutrition and Isoniazid for latent tuberculosis). He developed neutropenia as of May 15 (WBC 300). On May 25th, the patient developed an episode of dizziness and presyncope with a subsequent trauma to his left leg resulting in a superficial ulceration over the anterior shin. Neurology team diagnosed it as a vasovagal syncope. Two days later (May 27), he started to develop swelling of his left thigh with rapidly progressing erythema, significant tenderness mainly over the medial aspects of the thigh, and high grade fever (reaching 39), with fluctuation in his level of consciousness. EEG showed mild nonspecific diffuse disturbance in cerebral function. Infectious workup was taken; patient was started on piperacillin/tazobactam. Vascular and plastic surgery teams were consulted, duplex ultrasound of the lower extremities revealed no thrombosis. CT scan of the lower extremities revealed bilateral swelling in the fat planes with fat stranding—mainly on the left (Could not rule out necrotizing fasciitis due to the lack of contrast—preexisting kidney disease). His WBC was $100/\text{mm}^3$, procalcitonin 13 with lactic acidosis, antibiotics were rapidly escalated to meropenem and teicoplanin. He was maintained on GCSF twice daily. He had rapid worsening of thigh swelling and erythema suggesting necrotizing fasciitis with deterioration in his level of consciousness requiring intubation, hypotension, requiring IV fluid resuscitation and vasopressors, following which he had a cardiopulmonary arrest, picked up after 3 min of resuscitation, and was transferred to the intensive care unit. The patient was continued on medical treatment only (meropenem, teicoplanin, and anidulafungin). Surgery was excluded after discussion among a multidisciplinary team and the patient's family

given the high mortality associated with any surgical intervention. He initially continued to deteriorate, required maximum doses of dual vasopressors, and had acute kidney injury requiring continuous renal replacement therapy. The patient also showed the evidence of multiorgan failure (liver failure and coagulopathy). Immunosuppression (cyclosporine and mycophenolate mofetil) was discontinued and patient was started on hydrocortisone. Blood cultures grew *Clostridium perfringens* and we started metronidazole. On May 29, we initiated daily life-saving non-irradiated leukocyte transfusion, which was continued till June 11, from healthy eligible nonrelated donors stimulated with three doses of prednisone 20 mg starting 16 h before the collection and 1 dose of GCSF given 12 h prior to collection by apheresis. We noted improvement of absolute neutrophil counts (ANC) to $847/\text{mm}^3$ after the first infusion and was thereafter maintained above $1300/\text{mm}^3$ (Fig. 1), with no evidence of graft versus host disease (GVHD) or any other significant complication. Repeat CT scan of lower extremities on June 3, showed further progression of inflammatory/infectious disease of both lower extremities, mainly the left, compatible with necrotizing fasciitis. However, with the continued daily leukocyte transfusions and antibiotics, the patient started to improve clinically, with gradual decrease in his thigh swelling, erythema and tenderness, stabilization of his blood pressure, thus weaning off vasopressors. We stopped leukocyte transfusions when CBC revealed WBC $19,000/\text{mm}^3$ (PMNs 94%-ANC $18400/\text{mm}^3$, lymphocytes 1%, and monocytes 5%). Patient had gradual improvement in kidney function, was extubated and transferred to the floor for continuation of care. Bone marrow evaluation on June 10 showed cellular marrow, maturing trilineage hematopoiesis with no evidence of leukemia. The patient continued to improve, had physiotherapy and was discharged home on September while in complete remission, full donor chimerism and off immunosuppression.

Discussion and literature review

Despite their historical utilization for the prevention and treatment of severe infections associated with prolonged neutropenia, multiple controversies persist regarding the optimal use of granulocyte transfusion [1]. The available data suggest that granulocyte transfusions are best utilized as a temporary resource in life-threatening infections complicating transient neutropenia. The use of this form of blood product infusion therapy started since the 1930s with the use of buffy coat preparations [2]. Later, the modifications in the process used for the collection of granulocytes for transfusion aimed to improve the number of neutrophils collected, initially by using patients with chronic myeloid

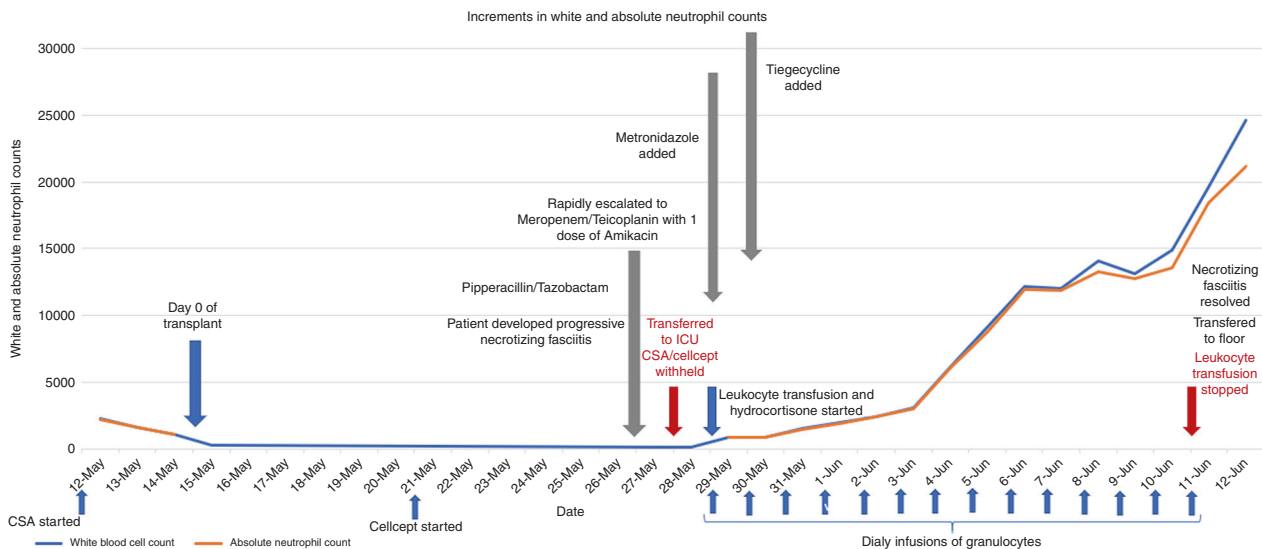


Fig. 1 Increments observed in white blood cell and absolute neutrophil counts with daily non-irradiated leukocyte transfusions. Legends: CSA: cyclosporin A

leukemia as donors [3], and subsequently through the use of healthy donors with GCSF and steroid stimulation [4, 5], since the prior method was associated with concerns regarding toxicities (33% compared with 12% with healthy donors) and the risk of GVHD with non-irradiated transfusions [6]. Data regarding efficacy of this cellular therapy came from multiple case series [7] and clinical trials [8], while other studies revealed negative results [9], and/or significant toxicity [10]. This explained the limited use of this treatment modality until the 1990s, where the combination of GCSF and steroids lead to significant improvement in the collection and patients' outcomes [11]. The contradictory results regarding its efficacy may be related to the variability of patients included, differences in preset indications to initiate granulocyte transfusions, timing of the initiation of transfusions, in addition to donor type and preparation, among multiple others.

Safdar et al. have reported retrospective results of the use of daily or alternating irradiated granulocyte transfusion between 2004 and 2007 at MD Anderson Cancer Center, including 74 patients with various neutropenia-associated infections [12], among which only 18 patients had underwent allogeneic SCT. Donors were either related or unrelated, stimulated by a single 8 mg dose of dexamethasone and GCSF (5 µg/kg body weight) 24 h before collection. Overall, 46% of patients stopped the infusions because of response or recovery of the neutrophil counts. Toxicity was noted in 11% of patients, and only 7% had to discontinue the infusions related to serious events. This analysis identified a greater benefit in patients with documented severe infections, and suggested the importance of timely initiation of this therapy as similarly reported before [13, 14].

The use of un-irradiated preparations has been proposed as a means to improve the efficacy of this treatment approach by allowing in vivo proliferation and expansion of stimulated myeloid progenitors. Leukemia patients post chemotherapy who received un-irradiated leukocyte transfusions had significant improvements in their long-term survival [15]. Freireich et al. had randomly assigned 108 patients to receive irradiated or non-irradiated leukocyte preparations (stimulated with a single dose of dexamethasone (8 mg) and GCSF (600 mcg) before collection by apheresis. This study revealed that non-irradiated products lead to the production of significantly higher elevations in the number of granulocytes (higher mean and median increments); as well as a higher proportion of patients achieving resolution of neutropenia [16], without any detrimental impact on overall survival or the eligibility for allogeneic SCT later; in addition to allowing in vivo proliferation of stimulated and differentiating myeloid progenitor cells [16]. The available data suggest an acceptable risk of GVHD (<1%) with a significant benefit if timely administration is initiated.

Nonetheless, multiple obstacles prevent the widespread utilization of granulocyte transfusions, and these also vary across countries. They include but are not limited to the availability of donors, logistical issues related to the timing of steroids/GCSF injections and appropriate collection/apheresis, the dose required and schedule of administration, in addition to ethical controversies and regulatory restrictions related to the administration of steroids and GCSF to healthy donors.

To our knowledge, this is the first case to be reported of the successful use of non-irradiated GCSF stimulated leukocyte

transfusion in a patient with a life-threatening infectious complication post haplo-SCT. The clinical improvement noted in our patient and the lack of any significant complication post transfusion suggest the efficacy and safety of this treatment strategy in cases of severe infections during prolonged and profound neutropenia, including the posttransplant setting. This however needs further exploration in a clinical trial to identify the optimal dosing, duration and frequency in this high-risk category of patients.

Acknowledgements We thank the nursing staff for providing excellent care for our patients and the physicians in the Hematology and Oncology division, various departments at the American University of Beirut Medical Center and referring physicians from Lebanon and the Middle East region for their significant contributions and dedicated patient care.

Author contributions NM collected data, provided clinical care, wrote and revised the manuscript. AM provided clinical care, contributed to and commented on the manuscript. IB provided clinical care, critical care support, and commented on the manuscript. ZK provided clinical care and commented on the manuscript. JE-C collected and analyzed data, provided clinical care, commented on and revised the manuscript. AB designed transplant program, provided clinical care, contributed to manuscript writing and edited the manuscript. All authors approved submission of the manuscript for publication purposes.

Compliance with ethical standards

Conflict of interest The authors declare that they have no conflict of interest.

Publisher's note Springer Nature remains neutral with regard to jurisdictional claims in published maps and institutional affiliations.

References

1. Gea-Banacloche J. Granulocyte transfusions: a concise review for practitioners. *Cytotherapy*. 2017;19:1256–69.
2. Strumia MM. The effect of leukocytic cream injections in the treatment of the neutropenias. *Am J Med Sci*. 1934;187:527–44.
3. Freireich L, Whang C, Bronson M. The function and fate of transfused leukocytes from donors with chronic myeloid leukaemia in leukopenic recipients. *Ann N Y Acad Sci*. 1964;113:1081–9.
4. Freireich EJ. Leukocyte transfusion and the development of the continuous-flow blood cell separator. *Transfus Med Rev*. 2011;25:344–50.
5. Bensinger WI, Price TH, Dale DC, Appelbaum FR, Clift R, Lilleby K, et al. The effects of daily recombinant human granulocyte colony-stimulating factor administration on normal granulocyte donors undergoing leukapheresis. *Blood*. 1993;81:1883–8.
6. Lowenthal RM, Grossman L, Goldman JM, Storing RA, Buskard NA, Park DS, et al. Granulocyte transfusions in treatment of infections in patients with acute leukaemia and aplastic anaemia. *Lancet* 1975;1:353–8.
7. Graw RG, Herzig G, Perry S, Henderson ES. Normal granulocyte transfusion therapy: treatment of septicemia due to gram-negative bacteria. *N Engl J Med*. 1972;287:367–71.
8. Vogler WR, Winton EF. A controlled study of the efficacy of granulocyte transfusions in patients with neutropenia. *Am J Med*. 1977;63:548–55.
9. Winston DJ, Ho WG, Gale RP. Therapeutic granulocyte transfusions for documented infections. A controlled trial in ninety-five infectious granulocytopenic episodes. *Ann Intern Med*. 1982;97:509–15.
10. Wright DG, Robichaud KJ, Pizzo PA, Deisseroth AB. Lethal pulmonary reactions associated with the combined use of amphotericin B and leukocyte transfusions. *N Engl J Med*. 1981;304:1185–9.
11. Stroncek DF, Yau YY, Oblitas J, Leitman SF. Administration of G-CSF plus dexamethasone produces greater granulocyte concentrate yields while causing no more donor toxicity than G-CSF alone. *Transfusion*. 2001;41:1037–44.
12. Safdar A, Rodriguez G, Zuniga J, Al Akhrass F, Pande A. Use of healthy-donor granulocyte transfusions to treat infections in neutropenic patients with myeloid or lymphoid neoplasms: experience in 74 patients treated with 373 granulocyte transfusions. *Acta Haematol*. 2014;131:50–58.
13. Rutella S, Pierelli L, Sica S, Serafini R, Chiusolo P, Paladini U, et al. Efficacy of granulocyte transfusions for neutropenia-related infections: retrospective analysis of predictive factors. *Cytotherapy*. 2003;5:19–30.
14. Grigull L, Pulver N, Goudeva L, Sykora KW, Linderkamp C, Beilken A, et al. G-CSF mobilised granulocyte transfusions in 32 paediatric patients with neutropenic sepsis. *Support Care Cancer*. 2006;14:910–6.
15. Guo M, Hu KX, Yu CL, Sun QY, Qiao JH, Wang DH, et al. Infusion of HLA-mismatched peripheral blood stem cells improves the outcome of chemotherapy for acute myeloid leukemia in elderly patients. *Blood*. 2011;117:936–41.
16. Freireich EJ, Lichtiger B, Mattiuzzi G, Martinez F, Reddy V, Kyle Wathen J. A prospective, randomized, double-blind study, comparing unirradiated to irradiated white blood cell transfusions in acute leukemia patients. *Leukemia*. 2013;27:861–5.