

The implications and management of complex biliary injuries at a tertiary hepatobiliary specialty center

SAGE Open Medical Case Reports
Volume 10: 1–6
© The Author(s) 2022
Article reuse guidelines:
sagepub.com/journals-permissions
DOI: 10.1177/2050313X221119587
journals.sagepub.com/home/sco



Rasha T Kakati^{1*} , Mohamad Othman^{2*}, Hussein Kharroubi^{3*}, Karim Ataya^{1*}, Hussein Nassar^{1*}, Bassel Hafez^{1*}, Walid Faraj¹ and Mohamad Jawad Khalife¹

Abstract

Injuries of the biliary tract and complex injuries involving vascular and parenchymal tissue can be detrimental despite the improved use of laparoscopy. Complex biliary injuries are variable depending on the type of injury as well as patient and surgeon factors. We present four cases of complex biliary injuries at our tertiary referral center with hepatobiliary expertise: biliary stenosis with obstruction, double duct system anatomy, combined right hepatic arterial transection and biliary duct injury, and a complete pedicle injury. Early identification and specialized repair of complex biliary injuries is essential to minimize patient morbidity. Notably, consulting a specialist intraoperatively in case of difficult dissection and visualization or a suspected injury and considering bail-out strategies such as a subtotal cholecystectomy or conversion are safe approaches to minimize complex biliary injuries. Earlier recognition and repair of complex biliary injuries improves outcomes when immediate intraoperative repair can be performed rather than delayed postoperatively.

Keywords

Complex biliary tract injury, cholecystectomy complications, parenchymal injury, vascular injury

Date received: 20 April 2022; accepted: 26 July 2022

Introduction

Biliary tract injuries are an uncommon complication of upper GI surgeries, with an incidence ranging between 0.5% and 1.5% of laparoscopic cholecystectomies in recent studies.^{1,2} Nevertheless, when encountered, these injuries are severely detrimental and vary depending on the injury and patient and provider factors, and suboptimal management may propagate biliary damage and patient morbidity.

Most commonly, the common bile duct (CBD) is mistaken for the cystic duct, resulting in clipping and division of the CBD. Strasberg delineates multiple mechanisms of biliary injuries, such partial occlusion of the biliary tree, most likely of an aberrant right hepatic duct, or circumferential injuries. Common factors contributing to biliary injuries include inflammation of the porta hepatis, variable portal anatomy, aggressive attempts at hemostasis, cauterization, blind clipping, and difficult vascular identification.^{3,4} This can often result in strictures and concomitant vascular injuries.

Vascular injuries may lead to complications due to resulting ischemia of the liver parenchyma and the biliary tree, atrophy, necrosis, and abscess or stricture formation.^{5,6} Moreover, vascular injuries render reconstruction more difficult, with poor prognosis associated with vascular and

¹Department of General Surgery, American University of Beirut Medical Center, Beirut, Lebanon

²Department of General Surgery, Faculty of Medicine and Medical Sciences, University of Balamand, Tripoli, Lebanon

³Faculty of Medicine, American University of Beirut, Beirut, Lebanon

*Co-first authors.

Corresponding Authors:

Rasha T Kakati, Department of General Surgery, American University of Beirut Medical Center, Bliss Street, PO Box 11-0236, Beirut, Lebanon.

Email: rtk12@mail.aub.edu

Mohamad Jawad Khalife, Department of General Surgery, American University of Beirut Medical Center, Bliss Street, PO Box 11-0236, Beirut, Lebanon.

Email: mk12@aub.edu.lb



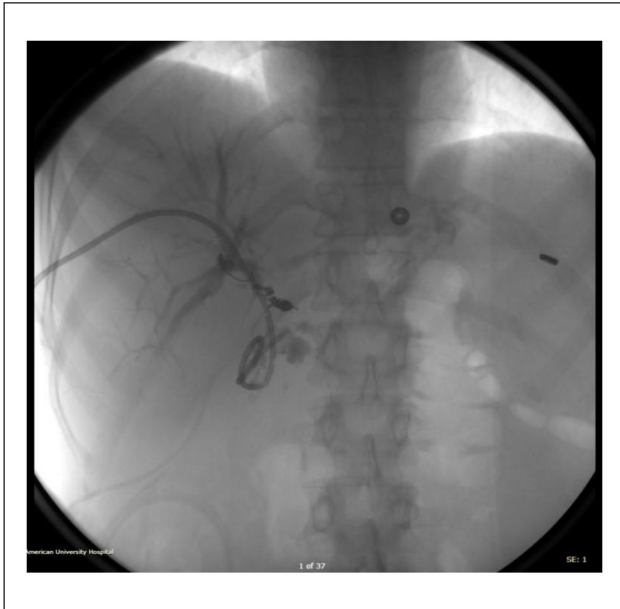


Figure 1. Trans-hepatic PTC reveals a stricture at the distal left biliary duct with bile draining into a collection adjacent to the proximal duodenum and severe narrowing of the second part of the duodenum.

parenchymal injuries when performed at centers that lack hepato-pancreato-biliary (HPB) expertise.⁵

The literature describes the management approaches to biliary injuries, guided by the various classifications of bile duct injuries such as the Corlette-Bismuth, Strasberg, and the more recent Stewart-Way classification, which incorporates vascular injury patterns.^{3,4} Nevertheless, biliary injuries are variable, and management is best tailored to a case-by-case basis to avoid serious, detrimental complications.⁵⁻⁷

Our tertiary healthcare center is a referral center that has encountered more than 100 biliary injuries to date. Most of these injuries have been discussed in the literature. We selected cases that we deemed rarely encountered, unique, or difficult to manage, with aims of contributing expertise management strategies to cases that may be minimally discussed, since understanding the impact of rare yet complex biliary injuries (CBI) and their efficient management is thus crucial to attain optimal patient outcomes when these injuries are encountered. We describe four cases of CBI examined retrospectively and discuss their etiologies, impact, and management approach at our center. The reported cases are in-line with the SCARE and PROCESS guidelines.^{8,9}

Case presentations

Case 1

A 30-year-old male patient with a history of cholelithiasis presented to our tertiary academic healthcare center's emergency department (ED) with postprandial right upper quadrant abdominal pain. He had previously presented with

biliary lithiasis at another rural hospital where several attempts at biliary stenting with endoscopic retrograde cholangiopancreatography (ERCP) had failed; he then underwent an exploratory laparotomy during which gallbladder visualization was deemed difficult and thus involved extensive CBD exploration and hepatic manipulation requiring insertion of a hepatic drain, cholecystostomy tube, and sub-hepatic Penrose drain. Few weeks later, the patient developed CBD stenosis and haemobilia for which he underwent hepatic artery stenting and was then referred to our center.

CT abdomen performed in our ED revealed a dilated biliary tree and a coil in the hepatic artery. Percutaneous cholangiography (PTC) demonstrated bile drainage into a collection with a CBD stricture and biliary drains out of place (Figure 1). The decision was to pursue surgery to relieve the collection and stenosis. Intraoperatively, left hepatic lobe and CBD necrosis were noted. We performed a left hepatectomy with Roux-en-Y hepaticojejunostomy (RYHJ) and inserted a biliary drain. Postoperatively, the patient was observed in the hospital for several days with no complications noted and his pain subsided. The patient was discharged in a stable condition and had no complaints at subsequent follow-up visits in clinic every few weeks.

Case 2

A 31-year-old female patient with a history of cholelithiasis was referred to our specialty hepatobiliary clinic from a peripheral hospital. Two weeks prior to presentation, she had undergone a laparoscopic cholecystectomy for symptomatic gallstones. Ten days after the surgery, she started experiencing right upper quadrant pain, fever, and jaundice. Subsequent ERCP showed complete blockage of the bile duct about 5 cm from the Sphincter of Oddi with proximal dilatation.

We performed an exploratory laparotomy, which revealed patchy areas of ischemia over the right hepatic lobe. One clip was found toward the bifurcation of the cystic duct with the common hepatic duct and another below it was obliterating part of the common hepatic duct (Figure 2). We dissected the porta hepatis and the common hepatic duct. The left hepatic artery was intact whereas the right hepatic artery was completely divided and clipped. We proceeded with hepatic artery reconstruction and Roux-en-Y hepaticojejunostomy (RYHJ) where the bile duct was divided proximally at the level of the confluence and both right and left hepatic ducts were sutured to the same anastomosis. The patient had a smooth hospital course and was discharged home after few days with no intra-operative or postoperative complications. The patient was seen in clinic several weeks later with no complaints.

Case 3

A 45-year-old female patient with a history of cholelithiasis presented to our ED with high-grade fever and severe abdominal pain. She had undergone a laparoscopic cholecystectomy at a peripheral hospital for symptomatic

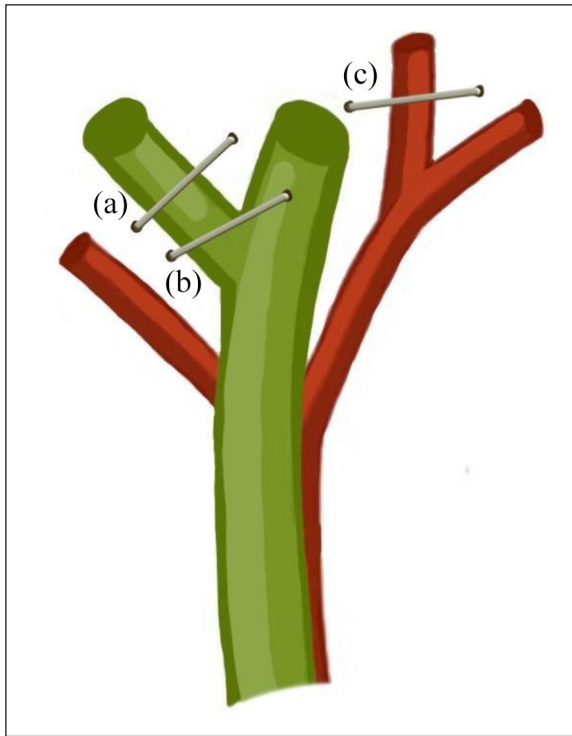


Figure 2. Clip locations noted in Case 2: (a) Toward the bifurcation of the cystic duct with the common hepatic duct, (b) obliterating part of the hepatic duct, and (c) completely transecting the right hepatic artery.

gallstones a few days prior to presenting, after which a CT scan demonstrated perihepatic and perisplenic fluid in the abdomen. Percutaneous drainage was attempted at the time and revealed bilious fluid. In light of her critical condition, she was referred to our center.

We performed an exploratory laparotomy and an intraoperative cholangiogram (IOC) which showed an intact biliary tree with no evidence of bile leak (Figure 3). Exploration of the porta hepatis revealed a second CBD with a transected lumen that was draining bile (Figure 4). A second cholangiogram was performed intraoperatively through that lumen and revealed an intact intrahepatic biliary duct (Figure 5). RYHJ was finally performed. The patient had a smooth hospital course over several days with no postoperative complications or complaints at multiple follow-up visits.

Case 4

A 50-year-old male patient was transferred to our intensive care unit (ICU) from a remote hospital after an open cholecystectomy. He had developed a massive bleed at the portal vein due to a retraction injury, and intraoperative control had led to more damage. The patient was unstable and in disseminated intravascular coagulation (DIC).

Surgery was performed, and a complete pedicle injury was identified (Figure 6). We mobilized and performed end-to-end anastomosis of the distal splenic vein and hepatic artery

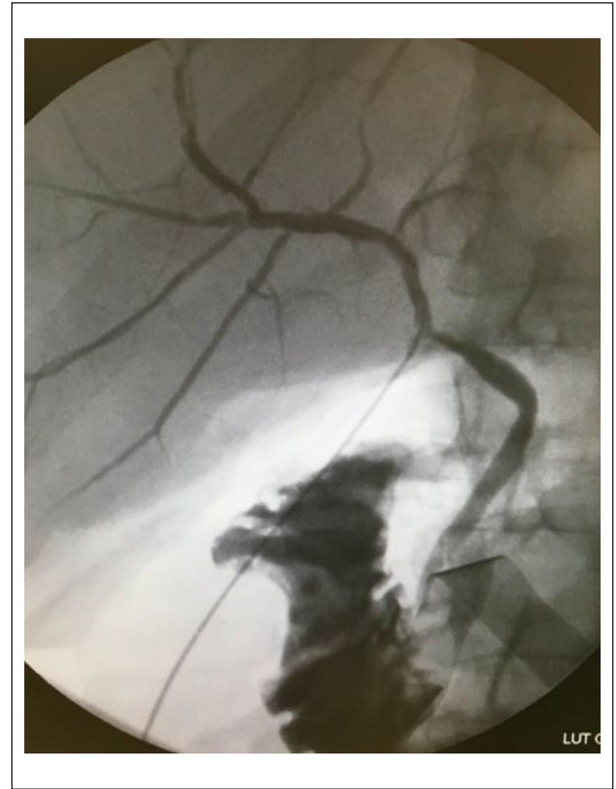

Figure 3. Intraoperative cholangiogram through the cystic duct stump.

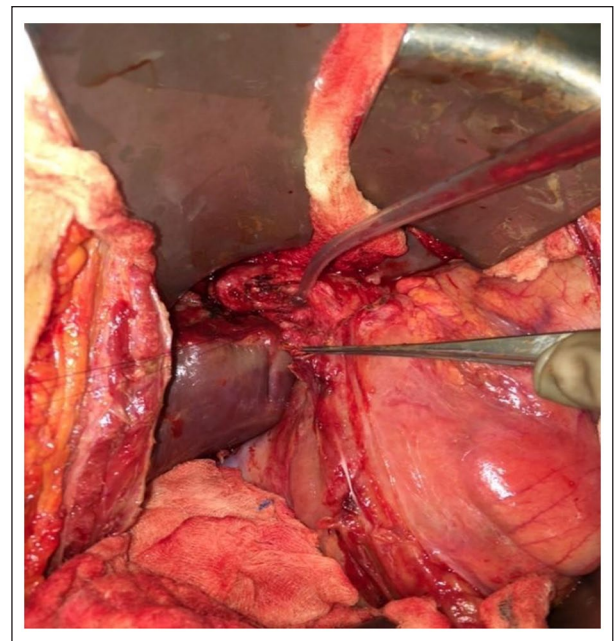


Figure 4. Transected double cystic duct lumen identified during exploration of the porta hepatis (pointed at by the forceps).

to the hepatic bed to restore blood flow through the hepatic vein and proximal hepatic artery, respectively. The patient's status was critical; thus, the repair of the bile duct injury was

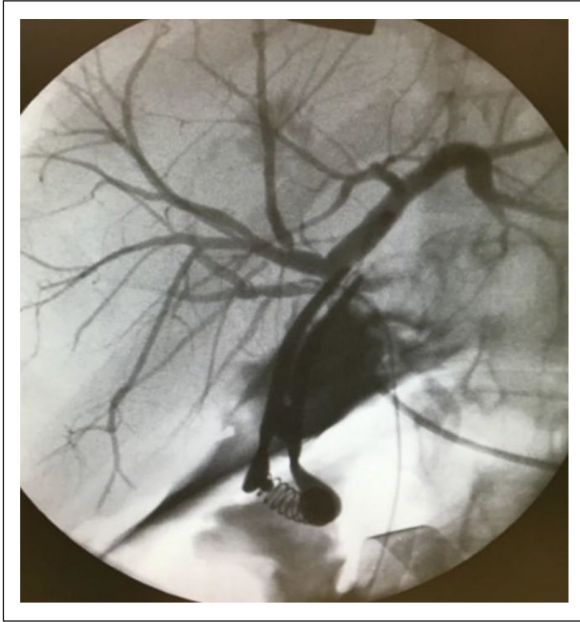

Figure 5. IOC done through the transected lumen identified during exploration of the porta hepatis.

completed at a second stage after stabilization. This two-stage procedure was effective at restoring biliary drainage and blood flow at the level of the pedicle after a complete injury. The patient tolerated both procedures well with no complications observed during his hospital stay and at follow-ups.

Discussion

Biliary stenosis with obstruction

The recommended management of biliary stenosis is endoscopic balloon insertion or stenting which are often reported to have high success rates at almost 90%.^{4,10,11} The second-line approach is percutaneous biloma drainage, which is a temporary palliative option.¹⁰ RYHJ can be considered next, especially in the case of complete transection and complex problems.¹¹

Our first patient experienced a bile duct injury after an exploratory laparotomy and an associated hepatic artery injury. Difficult visualization of the vasculobiliary system and blind repair may have contributed to this patient's initial injury. Moreover, attempts at mitigating the resulting postoperative complication of hemobilia through hepatic artery stenting may have further contributed to CBI as well as liver and CBD necrosis. A series of injuries and repairs may result in accumulated injuries that ensue persistent patient deterioration; it is thus necessary to target the most optimal and safe approach as early as possible. Moreover, prompt repair of biliary strictures is critical to avoid detrimental long-term sequelae including cholangitis or perforation.

RYHJ was our initial approach for this patient as neither stent placement nor percutaneous biloma drainage alone would target all complications seen in this patient. Time to

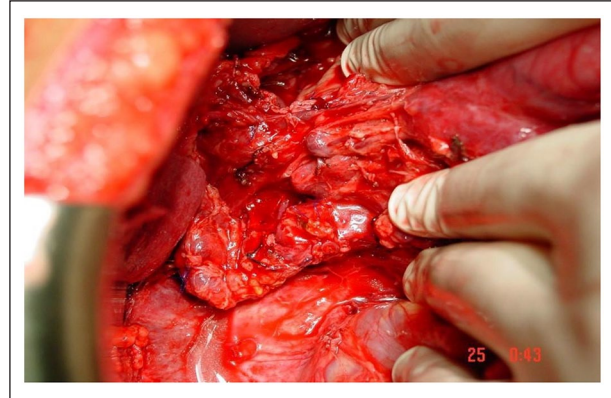


Figure 6. Complete pedicle injury with complete transection of the hepatic duct along with the portal vein and hepatic artery.

surgery is an essential concept in the management of biliary injuries, especially those with complex vascular complications. Although our patient was stable, it is essential to recognize and consider the multiple associated complications to proceed with the best first management approach for each patient.

Combined right hepatic arterial transection and biliary duct injury

When a bile duct is completely transected, two short segments can be approximated with an end-to-end anastomosis; however, this is typically associated with strictures and subsequent complications and low success rates.¹² With extensive biliary duct and vascular injuries, RYHJ may be the optimal option.

Inadvertent clipping during cholecystectomy is a common phenomenon that leads to biliary injury that can obstruct the CBD. Clipping of the vascular bed may lead to parenchymal compromise, as demonstrated in our second patient who experienced complete right hepatic artery transection leading to right hepatic lobe necrosis in addition to CBD stricture. This injury combination is not delineated as part of the established classifications, and the management is minimally discussed. It is essential to recognize the various injury combinations that could arise to best manage these patients.

Multiple complex injuries at several locations increase the repair time and make surgical repair more difficult with friable, injured tissue. Care must be taken to inspect the intraoperative field for injuries located in the triangle of Calot, but also at the proximal hepatic arteries in the porta hepatis. Early inspection and identification may spare further complications and the morbidity associated with repeat reparative surgery.

Double duct system anatomy

Double duct systems are a rare congenital anatomical duplication of the biliary tree. Both cholangiograms in our third

patient identified two different routes for biliary drainage. It is likely that the transected duct was also draining into the gallbladder, which is a rare, undescribed anomaly.

A double duct system can make biliary surgery more delicate as care should be taken to avoid injuries at multiple sites. This may also make biliary injuries more morbid for patients and make repairs more challenging, especially with the possibility of mistaking either of the CBDs as a cystic duct if the diagnosis is not realized prior to surgery.¹³ Preoperative recognition of double duct systems prevents unpreparedness in case of intraoperative identification of this anomaly or inadvertent injury prior to IOC. Some cases may be identified through ultrasound imaging. Nevertheless, if unidentified preoperatively, intraoperative caution with dissection alongside IOC is necessary to avoid iatrogenic biliary duct injuries especially with multiple ducts. An awareness of this anomaly and exercised caution with surgical technique may mitigate patient morbidity if double duct systems are encountered.

Complete pedicle injury

Injuries involving the vasculobiliary sheath can be performed without liver dissection by approaching the hepatic hilus but may be unsafe due to hazardous dissections with anatomical variations.¹⁴ Various bypass and shunting procedures for the repair of juxtahepatic venous injuries have been associated with vascular injury, thrombosis, and emboli.¹⁵ Our fourth patient with a complete pedicle injury presented to us in a critical state. A series of end-to-end anastomoses in the context of complete vasculobiliary transection in a two-stage procedure that prioritizes vascular repair can minimize procedural complications and patient morbidity. This is in comparison with primary repair or simultaneous vascular and biliary repair which we deem to demand more operative time and increase morbidity and mortality rates. Moreover, vascular injuries should be promptly addressed in order to reduce rates of liver and CBD infarction and necrosis, as well as the detrimental complication of biliary strictures. Thus far, our patient did not experience subsequent manifestations of vascular injuries or thromboembolic events following the described approach.

An overview of CBI

Despite a smooth postoperative course, all our patients required prolonged hospital admission. In addition, some patients needed ICU admissions due to their critical presentation. All four patients progressively experienced symptomatic improvement and clinical stability after CBI repair. Early identification and specialized repair of CBI is thus essential to reduce grave postoperative outcomes. Blind attempts at repair, especially with little experience and proficiency, may often pose more harm than benefit, and it is

essential to consider intraoperative specialist consultation in case of a suspected injury during HPB surgery, especially with CBI.¹⁶ All our procedures were performed by an experienced, trained hepatobiliary specialty surgeon.

Importantly, prevention of CBI is optimal. Identification of the critical view of safety (CVS) is an essential step of every cholecystectomy to avoid vasculobiliary injuries. In case intraoperative difficulty is encountered laparoscopically or the CVS is not discerned due to extensive fibrosis or obscuring inflammation, bail-out strategies such as a subtotal cholecystectomy is recognized as a safe approach.¹⁷ Awareness that “conversion is not crime” must also be raised.¹⁸ An open approach may even ease dissection while minimizing injuries attributed to depth perception or laparoscopic skills. Even so, careful inspection of the surgical field must be performed after completion of the surgery, since earlier recognition and repair of CBI improves outcomes when immediate intraoperative repair can be performed rather than delayed postoperatively.

Conclusion

Prevention of CBI through improved perioperative injury recognition, intraoperative skills, awareness of the management approaches for variable presentations of injuries, consulting specialists intraoperatively, and considering conversion are essential to reduce CBI rates. Understanding that early recognition and repair is key to minimizing morbidity from CBI even if encountered is essential to improving patient quality of life after a cholecystectomy.

Acknowledgements

RTK digitally illustrated Figure 2. This original image by the author is subject to protection and should not be duplicated without permission from the author.

Author contributions

MJK and WF performed the surgeries. Study concept and design: MJK, WF, RTK, and HK. Data collection: RTK, MO, HK, KA, BH, and HN. Writing the article: RTK, MO, HK, KA, BH, and HN. Editing the article: WF, RTK, and HK.

Declaration of conflicting interests

The author(s) declared no potential conflicts of interest with respect to the research, authorship, and/or publication of this article.

Funding

The author(s) received no financial support for the research, authorship, and/or publication of this article.

Ethics approval

Our institution does not require ethical approval for reporting individual cases or case series.

Informed consent

Written informed consent was obtained from the patient(s) for their anonymized information to be published in this article.

ORCID iD

Rasha T Kakati  <https://orcid.org/0000-0002-7623-4079>

References

1. Deziel DJ, Millikan KW, Economou SG, et al. Complications of laparoscopic cholecystectomy: a national survey of 4,292 hospitals and an analysis of 77,604 cases. *Am J Surg* 1993; 165(1): 9–14.
2. Rose JB and Hawkins WG. Diagnosis and management of biliary injuries. *Curr Prob Surg* 2017; 54(8): 406–435.
3. Jabłońska B and Lampe P. Iatrogenic bile duct injuries: etiology, diagnosis and management. *World J Gastroenterol* 2009; 15(33): 4097–4104.
4. Tringali A, Reddy DN, Ponchon T, et al. Treatment of post—cholecystectomy biliary strictures with fully—covered self—expanding metal stents—results after 5 years of follow-up. *BMC Gastroenterol* 2019; 19(1): 214.
5. Tzovaras G and Dervenis C. Vascular injuries in laparoscopic cholecystectomy: an underestimated problem. *Dig Surg* 2006; 23(5–6): 370–374.
6. Strasberg SM and Helton WS. An analytical review of vasculobiliary injury in laparoscopic and open cholecystectomy. *HPB (Oxford)* 2011; 13(1): 1–14.
7. Thomson BN, Parks RW, Madhavan KK, et al. Early specialist repair of biliary injury. *Br J Surg* 2006; 93(2): 216–220.
8. Agha RA, Borrelli MR, Farwana R, et al. The PROCESS 2018 statement: updating consensus Preferred Reporting Of CasE Series in Surgery (PROCESS) guidelines. *Int J Surg* 2018; 60: 279–282.
9. Agha RA, Borrelli MR, Farwana R, et al. The SCARE 2018 statement: updating consensus Surgical CASE REport (SCARE) guidelines. *Int J Surg* 2018; 60: 132–136.
10. Kapoor BS, Mauri G and Lorenz JM. Management of biliary strictures: state-of-the-art review. *Radiology* 2018; 289(3): 590–603.
11. Drapek LC, Kerlan RK Jr and Acquisto S. Guidelines for biliary stents and drains. *Chin Clin Oncol* 2020; 9(1): 9.
12. Stewart L and Way LW. Bile duct injuries during laparoscopic cholecystectomy: factors that influence the results of treatment. *Arch Surg* 1995; 130(10): 1123–1128; discussion 1129.
13. Chakravarty KD, Agarwal J and Praveen Kumar AC. Congenital double bile duct presenting as recurrent cholangitis in a child. *J Pediatr Surg Case Rep* 2015; 3(12): 548–550.
14. Yamamoto M, Katagiri S, Ariizumi S, et al. Glissonean pedicle transection method for liver surgery (with video). *J Hepatobiliary Pancreat Sci* 2012; 19(1): 3–8.
15. Manouras A, Pararas N, Antonakis P, et al. Management of major bile duct injury after laparoscopic cholecystectomy: a case report. *J Med Case Rep* 2009; 3(1): 44.
16. Chan KS, Hwang E, Low JK, et al. On-table hepatopancreatobiliary surgical consults for difficult cholecystectomies: a 7-year audit. *Hepatob Pancreat Dis Int* 2022; 21(3): 273–278.
17. Koo JGA, Chan YH and Shelat VG. Laparoscopic subtotal cholecystectomy: comparison of reconstituting and fenestrating techniques. *Surg Endosc* 2021; 35(3): 1014–1024.
18. Amirthalingam V, Low JK, Woon W, et al. Tokyo guidelines 2013 may be too restrictive and patients with moderate and severe acute cholecystitis can be managed by early cholecystectomy too. *Surg Endosc* 2017; 31(7): 2892–2900.