

Received: 2019.05.04

Accepted: 2019.09.26

Available online: 2020.01.24

Published: 2020.02.06

Surgical Treatment of Amiodarone-Induced Thyrotoxicosis in an Adult with Congenital Heart Disease: An Anesthetists Perspective

Authors' Contribution:

Study Design A
Data Collection B
Statistical Analysis C
Data Interpretation D
Manuscript Preparation E
Literature Search F
Funds Collection G

E 1 **Jose M. El-Asmar***
A 2 **Ahmad Salaheddine Naja***
A 3 **Eliane Al-Halabi**

1 Division of Urology, Department of Surgery, American University of Beirut Medical Center, Beirut, Lebanon

2 Division of Orthopedics, Department of Surgery, American University of Beirut Medical Center, Beirut, Lebanon

3 Department of Anesthesia, American University of Beirut Medical Center, Beirut, Lebanon

* Jose M. El-Asmar and Ahmad Salaheddine Naja contributed equally to the work and qualify as first authors

Eliane Al-Halabi, e-mail: elianehalabi@gmail.com

None declared

Corresponding Author:

Conflict of interest:

Patient: Male, 19-year-old
Final Diagnosis: Amiodarone induced thyrotoxicosis
Symptoms: Tachycardia
Medication: —
Clinical Procedure: Total thyroidectomy
Specialty: Anesthesiology

Objective: Unusual setting of medical care

Background: Amiodarone-induced thyrotoxicosis can be refractory to medical treatment seldom requiring surgical intervention. Herewith, we present the first case to date of amiodarone-induced thyrotoxicosis in a congenital heart disease post-Senning procedure requiring emergent surgical management.

Case Report: A 19-year-old-male patient with a history of a complex congenital heart disease developed severe pulmonary baffle stenosis and atrial fibrillation that was medically treated with amiodarone, upon which he developed. Amiodarone-induced thyrotoxicosis that was refractory to medical treatment. The patient was taken to the operating room for surgical treatment of his refractory disease. An intraoperative transesophageal echocardiography was employed ensuring adequate monitoring of his systemic vascular resistance and pulmonary arterial pressures.

Conclusions: Because of the high risk of cardiac complications induced by thyroid-induced thyrotoxicosis, patients with complex congenital heart disease require careful intraoperative monitoring in anticipation of tragic events. This is a report of a single case of successful operation on a patient in the thyrotoxic state.

MeSH Keywords: Amiodarone • Heart Defects, Congenital • Thyroid Crisis

Full-text PDF: <https://www.amjcaserep.com/abstract/index/idArt/917350>



1256



1



8



Background

Amiodarone is one of the most commonly prescribed antiarrhythmic drugs in the United States [1]. Nevertheless, multiple major side effects have been reported in the literature including but not limited to thyroid function dysregulation and even thyrotoxic crisis [2]. Ascribable to iodine rich constituent, amiodarone exhibited significantly increased risk of thyroid dysfunction. Amiodarone-induced thyrotoxicosis can seldom be refractory to medical treatment requiring a surgical intervention. To the best of our knowledge, no case reports in the literature have reported an emergent surgical treatment of amiodarone-induced thyrotoxicosis in a similar complex congenital heart disease patient.

We herein present a case of a 19-year-old male patient with a history of severely stenotic pulmonary venous baffle post-Senning procedure for transposition of great arteries, with a medically refractory amiodarone-induced thyrotoxicosis requiring emergent surgical management. This is a report of a single case of successful operation on a patient in the thyrotoxic state.

Case Report

A 19-year-old-male patient with a known history of congenital heart disease was admitted to the coronary cardiac unit for dyspnea, dry cough, and orthopnea. He had a history of transposition of great arteries with an atrial septal defect and a ventricular septal defect status post-Senning procedure at the age of 8 years. Consequently, he developed severe pulmonary venous baffle stenosis and atrial fibrillation that was medically treated with amiodarone for the past 2 years. However, he developed signs and symptoms of hyperthyroidism, and laboratory studies showed undetectable levels of thyroid stimulating hormone (TSH), free triiodothyronine (FT3) of 32.5 pg/mL (reference range 2.5–5 pg/mL) and free thyroxine level (FT4) of 7.7 ng/dL (reference range 0.98–1.63 ng/dL). A thyroid scan showed no uptake. Given the history, the patient was diagnosed with amiodarone-induced thyroiditis type 2. He was initially treated with a 3-week course of prednisone 40 mg once daily, however, his TSH levels remained undetectable throughout whereas FT3 and FT4 levels were 10.7 pg/mL and 7.5 ng/dL respectively. As such, amiodarone was discontinued. Methimazole, potassium iodide, and propranolol were added as treatment, leading to a partial clinical response with no improvement in laboratory results after 6 weeks of treatment. At the end of the 6 weeks of treatment, his TSH levels remained undetectable, yet FT3 and FT4 levels improved to 5.02 pg/mL and 6.2 ng/dL respectively. His hospital stay was complicated with high rate atrial fibrillation treated with digoxin.

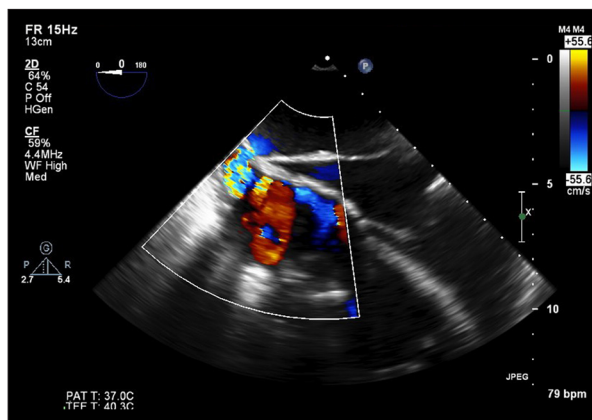


Figure 1. Intraoperative transesophageal echocardiography with color Doppler demonstrating the right atrial cavity highlighting the severe pulmonary baffle stenosis with a mean gradient of 20 mmHg. RA – right atrium; PVB – pulmonary venous baffle.

After multidisciplinary team discussion, a decision was made to proceed with surgical treatment. The high risk of morbidity and mortality was thoroughly discussed with the patient before consenting for surgery and general anesthesia.

A stress dose of steroids (hydrocortisone 100 mg) and magnesium sulfate were administered the morning of the surgery. The patient was initially sedated with dormicum 2 mg and fentanyl 50 mcg, the left radial pulse was localized, and the overlying skin was topicalized with lidocaine 2%. Following that, a left radial arterial line was placed. Defibrillator pads were also placed in the anterolateral position due to the high risk of cardiac arrhythmias. Thereafter, tracheal intubation was done following the administration of etomidate 14 mg, fentanyl 200 mcg, and rocuronium 40 mg.

Induction and intubation were smooth. Anesthesia was maintained with remifentanyl infusion (0.1–0.2 mcg/kg/min) and sevoflurane. Sevoflurane was adjusted according to the BIS monitor to keep a reading in the ranges of 40 to 60 and remifentanyl infusion rate was adjusted to maintain a blood pressure reading within the 20% range of his baseline. In addition, an intraoperative transesophageal echocardiography was employed, revealing a severely stenotic baffle with a mean gradient of 20 mmHg (Figure 1) with a dilated and diffusely hypokinetic right ventricle. No changes in the transesophageal echocardiography (TEE) imaging were noted intra-operatively. The surgical procedure lasted for 4 hours. The patient was hemodynamically stable throughout the entire procedure. Post-operative pain and nausea/vomiting were precluded with morphine sulfate 5 mg and ondansetron 4 mg respectively. The patient was extubated and transferred to the post-anesthesia care unit (PACU). He had a smooth post-operative course. One week following the procedure, a synchronized cardioversion was done,

and he successfully reverted to sinus rhythm. He was subsequently discharged 2 days later. At the time of discharge, TSH levels increased to 4.1 $\mu\text{U/mL}$ whereas fT_3 and fT_4 levels decreased to 0.65 and 0.59 respectively.

Discussion

Amiodarone is a potent antiarrhythmic agent, often used in the treatment of refractory arrhythmias. It has many side effects affecting various organs including the thyroid, skin, eye, and liver. Due to its high iodine content, amiodarone treatment interferes with thyroid autoregulation leading to the possibility of amiodarone-induced thyrotoxicosis. It can be divided into type 1 and type 2; the former being iodine-induced while the latter being a destructive thyroiditis type. Type 1 affects patients with a previous thyroid disorder resulting in excess synthesis of thyroid hormone caused by the presence of excess iodine. Consequently, it is treated by thionamides (methimazole) and potassium perchlorate to inhibit thyroid hormone synthesis and thyroid iodine uptake. Type 2 amiodarone-induced thyrotoxicosis, results from follicular disruption due to amiodarone cytotoxicity causing the release of preformed thyroid hormones. As such, the mainstay of treatment is limiting the inflammatory response through administration of glucocorticoids [3]. The constellations of physical examination and thyroidal radioactive iodine (RAI) uptake in our presented case, directed us towards the diagnosis of amiodarone-induced thyrotoxicosis type 2. Furthermore, amiodarone-induced thyrotoxicosis is associated with increased “major adverse cardiovascular events” such as cardiovascular mortality, myocardial infarct, stroke, heart failure, or ventricular arrhythmias requiring hospitalization [4]. Consequently, adults with congenital heart disease are particularly susceptible to amiodarone-induced thyroid dysfunction especially amiodarone-induced thyrotoxicosis [5]. Conventionally, it is recommended to revert hyperthyroid patients into a euthyroid state prior to thyroidectomy.

However, several case reports revealed minimal increase in morbidity and mortality upon performing thyroidectomy on hyperthyroid patients. In fact, many patients undergo surgery as first-line treatment of amiodarone-induced thyrotoxicosis [6].

References:

1. Vassallo P, Trohman RG: Prescribing amiodarone: An evidence-based review of clinical indications. *JAMA*. 2007; 298(11): 1312–22
2. Harris L, McKenna WJ, Rowland E et al: Side effects of long-term amiodarone therapy. *Circulation*, 1983; 67(1): 45–51
3. Khan A, Puttanna A, Raskauskiene D: Amiodarone-induced thyrotoxicosis: Type 1 or type 2? *BMJ Case Rep*, 2014; 2014: pii: bcr2014204485
4. Yiu K-H, Jim M-H, Siu C-W et al: Amiodarone-induced thyrotoxicosis is a predictor of adverse cardiovascular outcome. *J Clin Endocrinol Metab*, 2009; 94(1): 109–14
5. Moore BM, Cordina RL, McGuire MA, Celermajer DS: Adverse effects of amiodarone therapy in adults with congenital heart disease. *Congenit Heart Dis*, 2018; 13(6): 944–51
6. Pratap R, Qayyum A, Ahmad N, Jani P: Surgical management of amiodarone-induced thyrotoxicosis in a patient with Eisenmenger's syndrome: Literature review and case report. *J Laryngol Otol*, 2009; 123(11): 1276–79
7. Bartalena L, Bogazzi F, Chiovato L et al: 2018 European Thyroid Association (ETA) guidelines for the management of amiodarone-associated thyroid dysfunction. *Eur Thyroid J*, 2018; 7(2): 55–66
8. Farling PA: Thyroid disease. *Br J Anaesth*, 2000; 85(1): 15–28

Thyrotoxicosis is a potent meddler of the cardiac physiology, especially with an underlying cardiac disease. All patients with amiodarone-induced thyrotoxicosis require emergency management of their disease due to the irreversible repercussions on cardiac function. The European thyroid association recommends total thyroidectomy in case of deteriorating cardiac function despite a non-euthyroid state [7]. Our patient's preoperative hyperthyroid state required a categorical need for cautious intraoperative monitoring of his hemodynamic status to preclude the dreadful possibility of a thyroid storm through invasive blood pressure monitoring and echocardiographic imaging of the heart. As such, stress response had to be blunted by the adequate premedication ensuring appropriate dosage of opiates for intra-operative and post-operative pain management and a vigilant maintenance of normal core body temperature. The administration of magnesium sulphate was crucial in reducing the incidence and severity of dysrhythmias caused by intraoperative release of catecholamines [8]. Our high-risk patient with complex cardiac comorbidities, mainly pulmonary venous baffle stenosis, had an imminent risk of thyroid storm requiring careful intraoperative monitoring employed by invasive blood pressure monitoring and echocardiographic imaging of the heart. The main goals of anesthetic management were to maintain systemic vascular resistance, as well as to avoid further increase in pulmonary arterial pressure and excessive adrenergic stimulation.

Moreover, surgery appears to be a relatively safe option in comparison with no treatment or continuation of a failing medical treatment defined by minimal biochemical or clinical improvement.

Conclusions

Amiodarone is often used for the treatment of life threatening supraventricular and ventricular tachyarrhythmias. Moreover, amiodarone-induced thyrotoxicosis is highly associated with major cardiovascular side effects. In highly comorbid cardiac patients, similar to our patient in this case report, intraoperative echocardiographic imaging can be pivotal to maintain a dynamic monitoring of systemic vascular resistance and pulmonary arterial pressures.