

## CAS CLINIQUE / CASE REPORT

### INTRAMUSCULAR MYXOMA OF THE TIBIALIS ANTERIOR MUSCLE

#### First Report in the English Literature

<http://www.lebanesemedicaljournal.org/articles/64-4/case2.pdf>

Firas KAWTHARANI<sup>1</sup>, Patrick K. ZAKKA<sup>2\*</sup>, Hussein A. ZEINEDDINE<sup>2</sup>, Nabil YACCOUB<sup>3</sup>  
Karim Z. MASROUHA<sup>1</sup>, Said SAGHIEH<sup>1</sup>

Kawtharani F, Zakka PK, Zeineddine HA, Yacoub N, Masrouha KZ, Saghieh S. Intramuscular myxoma of the tibialis anterior muscle : first report in the English literature. J Med Liban 2016 ; 64 (4) : 242-244.

**ABSTRACT** • Intramuscular myxoma is a rare entity in itself, and while it has been described in several locations in the body, its presence in the tibialis anterior muscle has only been reported once in the literature. In this case report, we present, to our knowledge, the first case of an intramuscular myxoma in the tibialis anterior muscle in the English literature, which was successfully managed with wide surgical resection.

Keywords : myxoma, muscle neoplasm, skeletal muscle, soft tissue neoplasm

#### INTRODUCTION

Intramuscular myxomas (IM) are rare, benign neoplasms of mesenchymal origin. They have been described in various locations in the body, mainly in the thigh, shoulder, arm, buttock, lower leg, and trunk [1]. Myxomas lack a classical presentation as they vary depending on size and location. Yet, in almost all cases described, they are reported to be slow growing masses that rapidly enlarge [2]. These myxomas also lack unique radiological findings, necessitating a biopsy for their diagnosis, when indicated. The surgical approach for such lesions involves a wide surgical excision.

We herein describe the first case in the English literature of an IM of the tibialis anterior muscle, which was treated successfully with wide surgical excision.

#### CASE

A 45-year-old female presented to our Orthopedics clinic with a left anterior leg lump associated with discomfort. The patient noticed the lump two months prior to presentation, and it was noted to be slowly growing since then. It was associated with localized and intermittent anterior leg pain controlled by acetaminophen. She denied exacerbation of the pain upon movement or exertion. Her past

<sup>1</sup>Department of Surgery, Division of Orthopedic Surgery, American University of Beirut Medical Center (AUBMC), Beirut, Lebanon.

<sup>2</sup>Faculty of Medicine, American University of Beirut.

<sup>3</sup>Department of Radiology, AUBMC.

\*Correspondence : Patrick K. Zakka, MD.  
e-mail: pkz00@aub.edu.lb

Kawtharani F, Zakka PK, Zeineddine HA, Yacoub N, Masrouha KZ, Saghieh S. Myxome intramusculaire dans le muscle tibial antérieur : premier rapport dans la littérature anglaise. J Med Liban 2016 ; 64 (4) : 242-244.

**RÉSUMÉ** • Le myxome intramusculaire est une tumeur rare. Il a souvent été repéré dans différents organes du corps humain, mais sa présence dans le muscle tibial antérieur n'a été documentée qu'une seule fois.

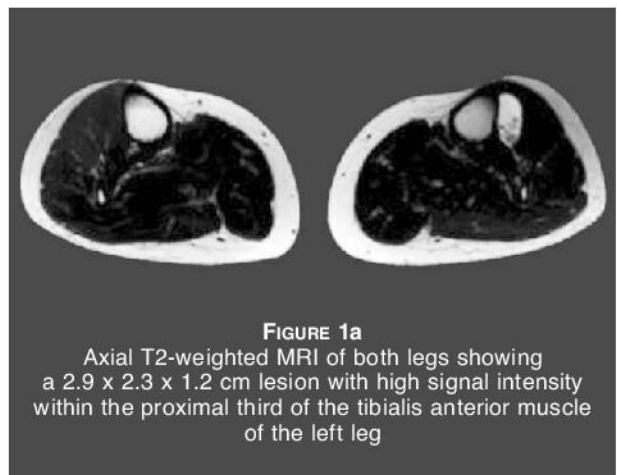
Dans ce rapport nous présentons, à notre connaissance, le tout premier cas de myxome intramusculaire dans la région du tibial antérieur décrit dans la bibliographie anglaise et qui a été traité avec succès par une large résection chirurgicale.

medical history was positive for hypertension, palpitations, and psoriasis. Her surgical history was positive for total abdominal hysterectomy.

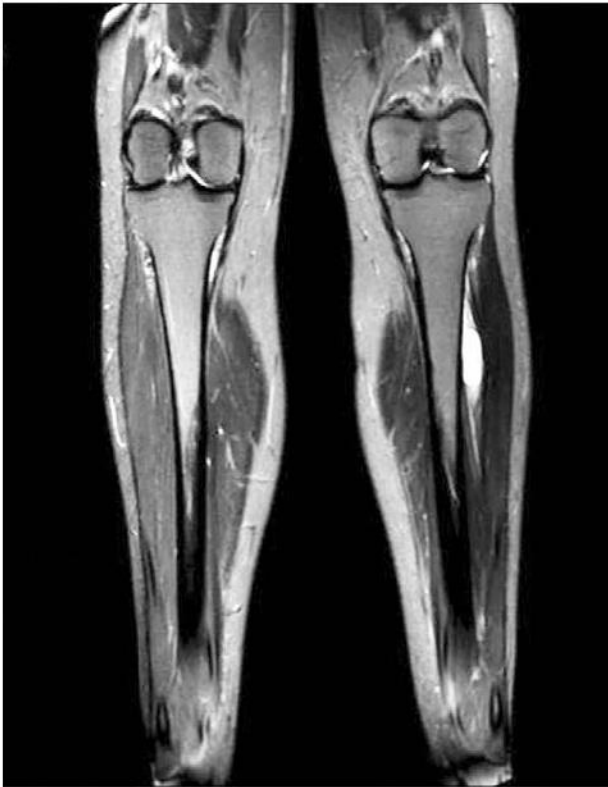On physical exam, a rubbery, mobile and minimally tender mass was palpable 7 cm distal to the left knee lateral joint line, on the pretibial aspect of the leg. Pulses were palpable, sensation was intact, and motor power in ankle dorsiflexion was complete.

Plain radiography revealed evidence of soft tissue swelling anteriorly over the proximal tibia. No associated bone or joint abnormalities were found.

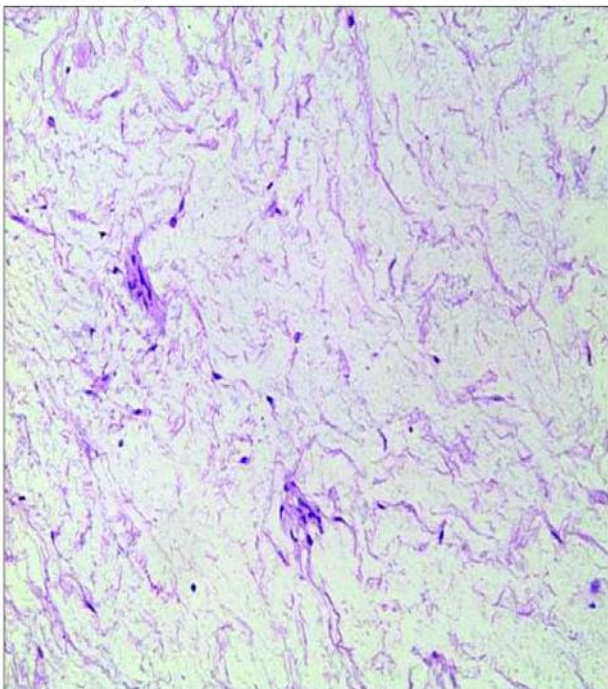
Magnetic resonance imaging (MRI) was performed, revealing a 2.9 cm x 2.3 cm x 1.2 cm sub-fascial lesion in the proximal third of the tibialis anterior muscle. The lesion was close to, but did not involve, the lateral cortex of the proximal tibial shaft (Figures 1a, 1b).



**FIGURE 1a**  
Axial T2-weighted MRI of both legs showing a 2.9 x 2.3 x 1.2 cm lesion with high signal intensity within the proximal third of the tibialis anterior muscle of the left leg



**FIGURE 1b.** Coronal T2-weighted MRI of both legs showing a 2.9 x 2.3 x 1.2 cm lesion with high signal intensity within the proximal third of the tibialis anterior muscle of the left leg. The cortex of the tibia is shown to be intact.



**FIGURE 1c.** High power histologic sample showing a myxoid stroma with few spindle shaped cells and no nuclear atypia. No vascular structures are seen. (H&E stain; Magnification x 400)

Our differential diagnosis of these findings included IM, low-grade sarcoma (e.g. fibromyxoid sarcoma) and nodular fasciitis. Due to the size of the tumor, a complete excision was planned.

A 5 cm incision was made on the lateral aspect of the subcutaneous border of the tibia, approximately 7 cm below the knee joint line. Subcutaneous dissection proceeded towards the tibialis anterior muscle, which was identified. Within the substance of the muscle, a cystic ganglion-like mass was identified and was removed with a cuff of normal skeletal muscle.

The retrieved specimen was a 3.5 cm x 2 cm x 1.5 cm soft tissue lesion surrounded by skeletal muscle. Grossly, the specimen appeared well defined and sectioning revealed a myxoid, soft, homogenous surface. Microscopic examination revealed the myxoid and benign nature of the lesion (Figure 1c). These findings were consistent with an IM.

#### DISCUSSION

Myxomas are rare, benign neoplasms consisting of undifferentiated stellate cells that originate from mesenchymal tissue. These cells are surrounded by a myxoid stroma of loose reticulin and collagen fiber matrix. It was first described in 1863 by Virchow, who brought forth the term to describe a tumor of benign nature that is histologically similar to the mucinous substance that is present in umbilical cord tissue [3]. Myxomas have been described in the skin, subcutaneous tissue, aponeurotic tissue, heart, bones, genitourinary tract, and muscular tissue.

Muscular myxomas comprise 15% to 17% of myxomas with an incidence of 1 per million per year, and a female to male predominance [4]. The mean age of presentation is 52 years [5]. Half of IM are located in the thigh [6], with other locations including the shoulder, arm, buttock, lower leg, and trunk [7]. The presented case is the first in the English literature to be described in the tibialis anterior muscle.

The clinical presentation of these lesions depends on their size and location and, as in this patient's case, they have generally been known to present as isolated lesions that are slow growing. These masses usually lie dormant for extended periods of time before suddenly enlarging [2]. They may, however, produce compressive symptoms on surrounding tissues and can occasionally be painful [7].

There are no pathognomonic findings on physical exam, laboratory tests, or imaging, necessitating a histological examination for diagnosis. In the setting of a small-sized lesion (less than 5 cm), an excisional biopsy, while also therapeutic, is needed for a definitive diagnosis [1]. Due to the small size of the tumor in the presented case it was indicated to perform a therapeutic and diagnostic wide excision rather than a core needle or open biopsy.

On gross appearance, IM can range in diameter from 2 cm to 20 cm, and can be oval or spherically shaped,

with an encapsulated appearance. Interstitial mucin, hypovascularization, few and scattered spindle-shaped stromal cells (hypocellularity), fine fibers of reticulin and strands of trabecular tissue are seen on histologic examination of IM biopsies. Degenerating muscle fibers may be seen at the periphery.

These myxomas have been and are easily misdiagnosed as malignant neoplasms, such as myxoid sarcomas, due to both their location in muscular compartments deep to fascia, and the occasional presence of crowded cellular foci within the myxomas [5]. It is important to recognize that even in the presence of hypervascular or hypercellular foci which are indicative of a malignant process, the absence of mitoses, nuclear atypia, and necrosis still point towards the presence of a benign lesion.

## CONCLUSION

In conclusion, IM is a rare entity, but the location of the myxoma in this particular muscle has never been reported in the English literature, with only one report in the German literature [8]. The lesion was managed by wide surgical excision after identifying it first by a plain radiograph followed by MR imaging. Histologic studies confirmed the diagnosis. It is important to recognize that although benign, hypercellular foci may be seen within the lesion, and this must be acknowledged to avoid diagnostic confusion. Although rare, such myxomas must remain in a physician's differential when dealing with soft tissue masses in the leg.

*The authors report no financial conflict of interest.*

## REFERENCES

1. Dormand EL, Prabhu-Desai A, Rice AJ, Rosin RD. Not all pain in the left iliac fossa is diverticular disease: a case study of a psoas myxoma and review. *Surgeon* 2006; 4: 239-43.
2. Rashid A, Abdul-Jabar HB, Karmani S, Rezajooi K, Casey AT. Giant paravertebral myxoma. *Eur Spine J* 2011 Jul 20; Suppl 2: S138-S142.
3. Virchow RL (editor): *Cellular pathology as based upon physiological and pathological histology*, Philadelphia. Pa: Lippincott, 1863: 525-526.
4. Hashimoto H, Tsuneyoshi M, Daimaru Y, Enjoji M, Shinohara N. Intramuscular myxoma. A clinicopathologic, immunohistochemical, and electron microscopic study. *Cancer* 1986; 58: 740-7.
5. Nielsen GP, O'Connell JX, Rosenberg AE. Intramuscular myxoma: a clinicopathologic study of 51 cases with emphasis on hypercellular and hypervascular variants. *Am J Surg Pathol* 1998; 22 (10): 222-7.
6. Shugar JM, Som PM, Meyers RJ, Schaeffer BT. Intramuscular head and neck myxoma: report of a case and review of literature. *Laryngoscope* 1987; 97: 105-7.
7. Silver WP, Harrelson JM, Scully SP. Intramuscular myxoma: a clinicopathologic study of 17 patients. *Clin Orthop Relat Res* 2002; 403: 191-7.
8. Luebke AM, Gocke C, Priemel M, Grob TJ, Zustin J. Intramuscular myxoma of the lower leg. *Pathologe* 2013; Jul; 34 (4): 360-3 [German].