

CASE SERIES

Immunotherapy for metastatic liver disease from colorectal carcinoma: case series from the Middle East

Rasha T. Kakati¹, Walid Faraj¹, Taha Qaraqe¹, Frederic El Chaer¹, Hero Hussain², Ali Shamseddine^{3,†} and Mohamad Jawad Khalife^{1,†,*}

¹Department of General Surgery, American University of Beirut Medical Center, Beirut, Lebanon

²Department of Diagnostic Radiology, American University of Beirut Medical Center, Beirut, Lebanon

³Department of Internal Medicine, Hematology and Oncology, American University of Beirut Medical Center, Beirut, Lebanon

*Correspondence address. Department of General Surgery, Liver Transplantation and Hepatopancreaticobiliary Unit, American University of Beirut Medical Center, PO Box 11-0236, Bliss Street, Beirut, Lebanon. E-mail: mk12@aub.edu.lb

†A. Shamseddine and M. J. Khalife are Senior Researchers.

Abstract

Immunotherapy poses new considerations and alterations to the management of metastatic colorectal carcinoma (mCRC), where chemotherapy achieves complete radiological response but yields complete pathological response in few patients only. Immunotherapy may be superior in the conversion of unresectable disease to resectable liver lesions from mCRC and downsizing borderline lesions for more feasible resectability and achieving complete pathologic response, with the potential for cure and to alter current, established guidelines for surgical resection with a shift from chemotherapy. We present two patients with hepatic lesions from mCRC characterized by deficient mismatch repair (dMMR) which were unresectable after traditional chemotherapy but were converted to resectable lesions with a complete histopathological response following immunotherapy. Complete histopathologic response and radiologic regression or disappearance of liver lesions was observed in patients with dMMR mCRC after pembrolizumab. Immunotherapy exhibits notable potential for cure, achieving complete, successful surgical resection and improving prognosis.

INTRODUCTION

Colorectal carcinoma (CRC) is the third most commonly occurring cancer in males and the second in females; the liver is the most common metastatic organ for CRC [1, 2]. Stangl *et al.* reported a median survival of 31, 7.9, 2.6 and 0.9 at 1, 2, 3 and 4 years, respectively, for patients with metastatic colorectal carcinoma (mCRC); even with chemotherapy, the 5-year survival rates remain low at around 9% [3].

Surgical resection remains the gold standard for metastatic liver lesions in mCRC while improving survival rates [4]. Current guidelines suggest that any resectable tumor should be resected with a complete (R0) resection intention with at least a 20% functional residual volume [5–7].

As initial curative resection is not always possible, patients with unresectable liver lesions require chemotherapy to downsize those lesions and control micrometastases, hence converting 15% of the 10–25% of patients with initially unresectable disease to resectable candidates [5, 8, 9]. Complete response is observed in only 9% of patients receiving chemotherapy [10].

The advancement in targeted therapies, mainly immunotherapy, provides potential for improving response, achieving complete surgical resection and achieving better survival rates. Microsatellite instability-high (MSI-H) mCRC occurs due to mutations in mismatch repair (MMR) genes, leading to silenced or malfunctioning of the MMR proteins, including MutL Homolog 1 (MLH1), MutS Homolog 2 (MSH2), MutS Homolog 6 (MSH6) and PMS1 Homolog 2 (PMS2), which normally complex to recognize mismatch and guide repair, yielding deficient mismatch repair (dMMR) tumors [1, 11, 12]. Tumor cells express Programmed Death-Ligand 1 (PD-L1) which, when recognized by Programmed Death-1 on cytotoxic T-cells, blocks the immune response, allowing perpetuation of cancer cells [13]. Blockade with anti-PD-L1 antibodies, such as pembrolizumab, has thus been considered to overcome dMMR tumor cells, with promising results shown with various cancers [13]. Intermittent results from the Phase II KEYNOTE-016 and CHECKMATE 142 trials culminated in the approval and advocacy for the use of pembrolizumab by the National Comprehensive Cancer Network and the Food and Drug Adminis-

Received: January 18, 2022. Accepted: March 17, 2022

Published by Oxford University Press and JSCR Publishing Ltd. All rights reserved. © The Author(s) 2022.

This is an Open Access article distributed under the terms of the Creative Commons Attribution Non-Commercial License (<https://creativecommons.org/licenses/by-nc/4.0/>), which permits non-commercial re-use, distribution, and reproduction in any medium, provided the original work is properly cited. For commercial re-use, please contact journals.permissions@oup.com

tration (FDA) since 2017 for recurrent or mCRC, which is MSI-H/dMMR [1, 14]. Notably, KEYNOTE-177, a new Phase III randomized controlled trial investigating the efficacy and safety of pembrolizumab, was launched in 2015 with early suggestions for superiority as first-line therapy with improved progression-free survival (PFS) at 16.5 months compared to 8.2 months with chemotherapy [1, 15].

In light of this, immunotherapy shows very promising results in patients with mCRC; in particular, pembrolizumab can convert unresectable disease, downsize borderline lesions and achieve R0 resection after surgery. We are reporting a case series of two patients who showed complete histopathological response after immunotherapy.

CASE PRESENTATION

First case

A 33-year-old female patient was diagnosed with a moderately differentiated invasive adenocarcinoma of the transverse colon with multiple bilobar liver lesions (Fig. 1A1 and Table 1). She underwent a laparoscopic subtotal colectomy, and the immunohistochemical analysis showed loss of MLH1 and PMS2 expression in tumor cells with retained MSH2 and MSH6, thus MMR-deficient (dMMR). She was started on FOLFOX (Oxaliplatin with 5-Fluorouracil and Leucovorin) regimen with Avastin (Bevacizumab). Computed tomography (CT) scan was performed after her fourth cycle of chemotherapy and revealed an increase in size of the liver lesions (Table 1). She was started on pembrolizumab (19 cycles), and upon follow-up CT scans done every 3 months, there was a significant decrease in the size of the hepatic lesions (Fig. 1A2). She was reassessed and underwent liver resections of all her lesions. Final pathology was negative for residual carcinoma, with areas of necrosis and negative margins on surgical pathology.

Second case

A 33-year-old male patient was diagnosed with adenocarcinoma of the transverse colon with 24 bilobar hepatic metastases. He was started on four cycles of Xelox and Avastin after which some lesions responded to treatment while others did not, as evidenced by changes in the hepatic lesions on magnetic resonance imaging (MRI) (Fig. 1B1 and Table 1). Immunohistochemical analysis showed loss of MLH1 and PMS2 with retention of MSH2 AND MSH6; he was started on pembrolizumab (12 cycles) with consistent interval decrease in size of both the colonic mass and hepatic lesions over several follow-ups every 3 months (Table 1). After multiple months, MRI showed a marked decrease in the transverse colonic mass and all hepatic lesions which became necrotic; four hepatic lesions became barely visible or disappeared (Table 1 and Fig. 1B2). He underwent a transverse colectomy with primary anastomosis and metastasectomy where all hepatic lesions were negative for residual carcinoma with negative surgical margins and areas of necrosis.

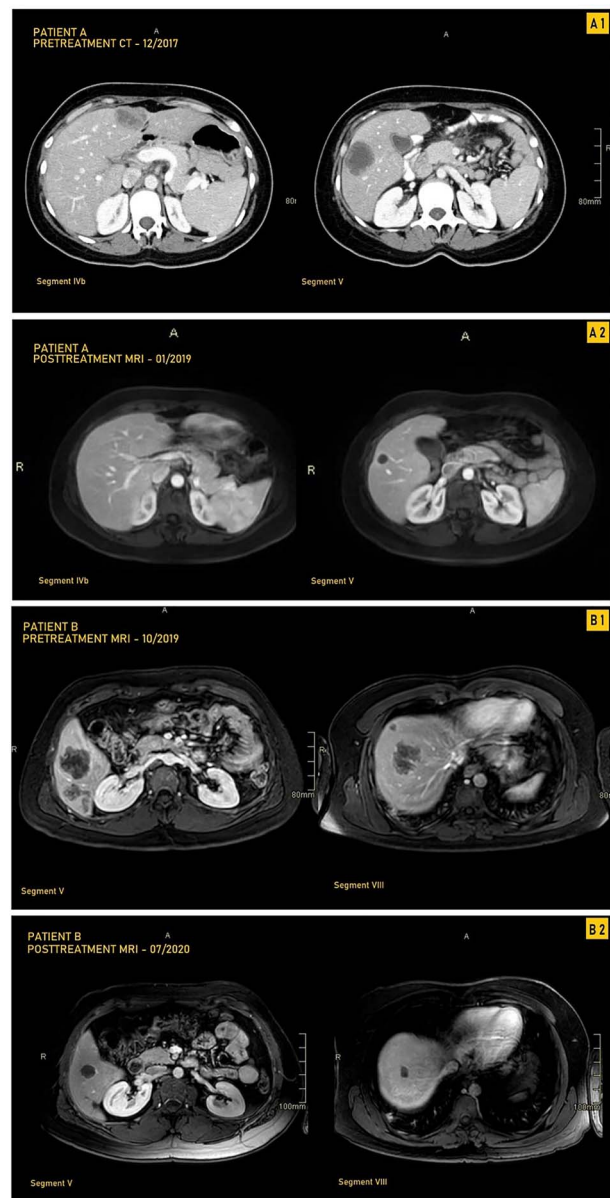


Figure 1. CT and MRI images of our two patients before and after treatment with pembrolizumab; **(A1)** Pretreatment MRI of our first patient in September 2017 showing most prominent lesions, located in Segments IVb and V, on axial enhanced CT after contrast administration; **(A2)** Posttreatment axial enhanced T1-weighted MRI of our first patient in January 2019 showing most prominent lesions located in Segments IVb and V; the lesion in Segment V is smaller, measuring 1.4 cm, and is completely necrotic; **(B1)** Pretreatment axial enhanced T1-weighted sequence MRI performed on 3Tesla field strength following gadolinium contrast administration in our first patient in October 2019 showing most prominent lesions, located in Segments V and VIII; the largest metastatic lesion is a 4.8-cm heterogeneously enhancing metastatic lesion in Segment VIII; **(B2)** Posttreatment axial enhanced T1-weighted sequence MRI performed on 3Tesla field strength following gadolinium contrast administration in the hepatobiliary phase in our second patient in July 2020, showing most prominent lesions located in Segments V and VIII; the largest lesion in Segment VIII decreases in size to 1.5 cm following treatment and is completely necrotic.

DISCUSSION

In light of the high occurrence of liver metastases among patients with mCRC, achieving complete histopathologic response and a successful surgical cure is essential.

Table 1. Progression of size and response as noted on CT and MRI of hepatic metastatic lesions and the colonic mass at different points of the treatment course in our two patients

Imaging date	Treatment stage	Segment/location	No. of lesions per segment	Size of largest lesion (cm)	Response
First patient					
September 2017	Initial presentation prior to therapy initiation	Segment I	None	-	Baseline
		Segment II	1	1.7 × 1.5	
		Segment III	None	-	
		Segment IVa	None	-	
		Segment IVb	1	2.1 × 1.7	
		Segment V	2	1.6 × 1.5	
		Segment VI	None	-	
		Segment VII	1	1.1 × 0.7	
		Segment VIII	None	-	
		Colon	1	6.2 × 4.1 × 3.8	
December 2017	After subtotal colectomy, Folfox and Avastin	Segment I	None	-	-
		Segment II	1	3.4 × 3	Increase in size
		Segment III	None	-	-
		Segment IVa	None	-	-
		Segment IVb	1	4 × 2.5	Increase in size
		Segment V	2	4.1 × 3.4 and smaller 2.2 × 1.8	-
		Segment VI	None	-	-
		Segment VII	1	0.9 × 0.8	Decrease in size
		Segment VIII	None	-	-
		Colon	None	-	Resected
January 2019	After 19 cycles of pembrolizumab and prior to metastasectomy	Segment I	None	-	-
		Segment II	1	0.9 × 0.8	Decrease in size
		Segment III	None	-	-
		Segment IVa	None	-	-
		Segment IVb	1	1.4 × 0.9	Decrease in size
		Segment V	2	1.4 × 1.3 and smaller 0.7 × 0.6	Decrease in size
		Segment VI	None	-	-
		Segment VII	1	0.5 × 4	Decrease in size
		Segment VIII	None	-	-
		Colon	None	-	Resected
Second patient					
October 2019	After receiving four cycles of Xelox and Avastin	Segment I	1	1.9 × 1.2	Baseline
		Segment II	2	2.7 × 2.1	
		Segment III	None	-	
		Segment IVa	1	1 × 0.9	
		Segment IVb	None	-	
		Segment V	5	4.7 × 4.5	
		Segment VI	5	4.2 × 3.7	
		Segment VII	4	1.7 × 1.3	
		Segment VIII	6	4.8 × 4.1	
		Colon	1	4.5 × 2.9	
July 2020	After 12 cycles of pembrolizumab and prior to metastasectomy	Segment I	0	-	Zero of one—lesion no longer seen
		Segment II	2	1.1 × 0.7	Decrease in size
		Segment III	None	-	-
		Segment IVa	1	0.4 × 0.4	Decrease in size
		Segment IVb	None	-	-
		Segment V	4	2.2 × 1.9	Four of five lesions—one lesion no longer seen, four decreased in size
		Segment VI	5	1.3 × 1	Decrease in size
		Segment VII	4	0.3	Decrease in size
		Segment VIII	4	1.5 × 1.2	Four of six lesions—two lesions no longer seen, four lesions decreased in size
		Colon	1	1.7 × 1.5	Decrease in size

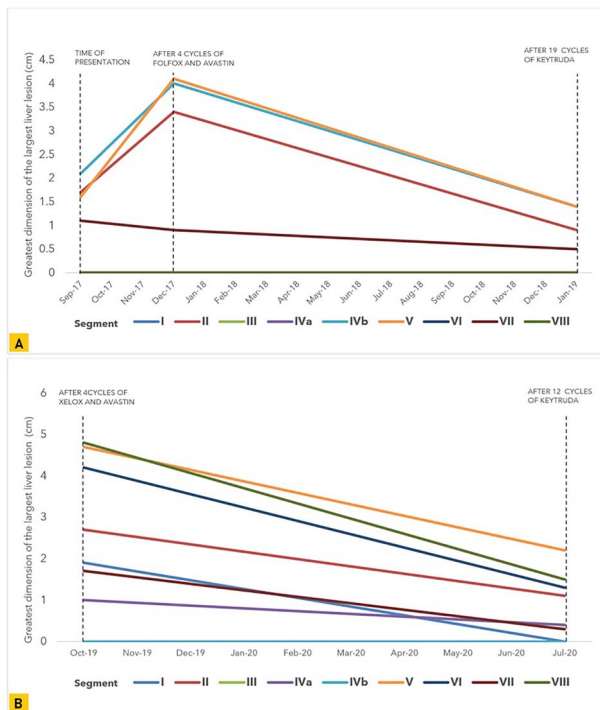


Figure 2. Graphical representation of the trend in size of the greatest tumor dimension of the largest liver lesions noted on CT and MRI in each liver segment at multiple points during the course of treatment in (A) our first patient and (B) our second patient.

Where chemotherapy provides questionable resectability changes for hepatic lesions, the necessity for improved response preoperatively is essential for improved clinical course, quality of life and survival. Two patients were diagnosed with dMMR colorectal carcinoma metastatic liver lesions.

Despite receiving prior chemotherapy which imparted an overall increase in the size of the metastatic hepatic lesions in our second patient, pembrolizumab demonstrated efficacy in reducing all lesions; this was also observed in our first patient when used as first-line treatment (Fig. 2). Neither patient reported adverse effects; they both experienced a smooth clinical course during follow-up.

Among both patients, complete histopathological response was demonstrated after surgery in all resected hepatic specimens. Multiple considerations surface regarding the potential of immunotherapy to modify pre-surgical management to ensure complete response and successful surgical resection with among this patient population. We demonstrate that immunotherapy poses a potential to achieve both complete histopathologic and radiologic responses.

The concept of resectable disease has potential to evolve with this novel treatment strategy; patients with hepatic lesions considered impossible to resect can now be considered as candidates for successful surgical management and cure from CRC. These considerations, in addition to surgical experience and the rise in molecular diagnostic techniques, have the potential to revise and

impart modifications on currently established principles guiding pre-surgical management to attain effective surgical resection.

In line with our findings, in June 2020, the FDA approved pembrolizumab for the first-line treatment of patients with unresectable or metastatic MSI-H/dMMR CRC due to ongoing KEYNOTE-177 results. Furthermore, in December 2020, official KEYNOTE-177 findings were released, demonstrating a 2-fold increase in PFS among patients receiving first-line pembrolizumab, confirming and enhancing our findings alongside [16]. Immunotherapy can change the concept of surgical management of patients with mCRC to the liver, not only by improving PFS but also by achieving complete histopathologic response and attaining cure. We envision notable curative potential and recommend clinical trials investigating histopathologic response to pembrolizumab in a large sample of patients with mCRC to the liver.

CONCLUSION

Complete histopathologic response of liver lesions with pembrolizumab in patients with dMMR mCRC exhibits notable potential for cure and achieving complete, successful surgical resection. We demonstrate 100% histopathologic response as well as radiologic regression or disappearance in 29 lesions among one patient receiving first-line pembrolizumab and another patient receiving pembrolizumab after progression with chemotherapy. This poses notable considerations to further investigate pembrolizumab as a novel treatment strategy with curative potential confirmed after resection to improve prognosis.

CONFLICT OF INTEREST STATEMENT

None declared.

FUNDING

None.

CONSENT FOR PUBLICATION

Both patients provided consent to publish these findings.

REFERENCES

- Atreya CE, Yaeger R, Chu E. Systemic therapy for metastatic colorectal cancer: from current standards to future molecular targeted approaches. *Am Soc Clin Oncol Educ Book* 2017;**37**: 246–56.
- Tomlinson JS, Jamagin WR, DeMatteo RP, Fong Y, Kornprat P, Gonen M, et al. Actual 10-year survival after resection of colorectal liver metastases defines cure. *J Clin Oncol* 2007;**25**:4575–80.
- Stangl R, Altendorf-Hofmann A, Charnley RM, Scheele J. Factors influencing the natural history of colorectal liver metastases. *Lancet* 1994;**343**:1405–10.

4. Wilson SM. Surgical treatment of hepatic metastases from colorectal cancers. *Arch Surg* 1976;**111**:330.
5. Berri RN, Abdalla EK. Curable metastatic colorectal cancer: recommended paradigms. *Curr Oncol Rep* 2009;**11**:200–8.
6. Khatri VP, Petrelli NJ, Belghiti J. Extending the frontiers of surgical therapy for hepatic colorectal metastases: is there a limit? *J Clin Oncol* 2005;**23**:8490–9.
7. Pawlik TM, Vauthey J-N. Surgical margins during hepatic surgery for colorectal liver metastases: complete resection not millimeters defines outcome. *Ann Surg Oncol* 2008;**15**:677–9.
8. Tanaka K, Takakura H, Takeda K, Matsuo K, Nagano Y, Endo I. Importance of complete pathologic response to prehepatectomy chemotherapy in treating colorectal cancer metastases. *Ann Surg* 2009;**250**:935–42.
9. Bismuth H, Adam R, Lévi F, et al. Resection of nonresectable liver metastases from colorectal cancer after neoadjuvant chemotherapy. *Ann Surg* 1996;**224**:509–22.
10. Blazer DG, Kishi Y, Maru DM, Kopetz S, Chun Y, Overman M, et al. Pathologic response to preoperative chemotherapy: a new outcome end point after resection of hepatic colorectal metastases. *JCO* 2008;**26**:5344–51.
11. Jonson I, Ougland R, Larsen E. DNA repair mechanisms in Huntington's Disease. *Mol Neurobiol* 2013;**47**:1093–102.
12. Sinicrope FA, Sargent DJ. Molecular pathways: microsatellite instability in colorectal cancer: prognostic, predictive, and therapeutic implications. *Clin Cancer Res* 2012;**18**:1506–12.
13. Salman P, Panay S, Fernández R, Mahave M, Soza-Ried C. Evidence of response to pembrolizumab in a patient with lynch syndrome-related metastatic colon cancer. *Oncol Targets Ther* 2018;**11**:7295–300.
14. Vranic S. Microsatellite instability status predicts response to anti-PD-1/PD-L1 therapy regardless the histotype: a comment on recent advances. *Bosn J Basic Med Sci* 2017;**17**:274–5.
15. Andre T, Shiu K-K, Kim TW, Jensen BV, Jensen LH, Punt CJA, et al. Pembrolizumab versus chemotherapy for microsatellite instability-high/mismatch repair deficient metastatic colorectal cancer: the phase 3 KEYNOTE-177 study. *JCO* 2020;**38**:LBA4-LBA4.
16. André T, Shiu K-K, Kim TW, Jensen BV, Jensen LH, Punt CJA, et al. Pembrolizumab in microsatellite-instability-high advanced colorectal cancer. *N Engl J Med* 2020;**383**:2207–18.