

# Ustekinumab Successfully Treats and Maintains Remission of Pyostomatitis Vegetans Associated with Crohn's Disease

Sarah Abi Doumeth, MD,<sup>\*†</sup> Ossama Abbas, MD<sup>‡</sup> and Jana G. Hashash, MD, MSc<sup>\*</sup>

Pyostomatitis vegetans (PV) is a rare inflammatory stomatitis often associated with inflammatory bowel diseases (IBD). Treatment of PV depends on the presence of coexisting IBD. To date, there have been no reports on the use of ustekinumab for PV. There have been recent cases on the use of ustekinumab for treatment of pyoderma gangrenosum and uveitis. We report the case of a 26-year-old female with moderately severe Crohn's disease (CD) and PV who was successfully treated with ustekinumab monotherapy. Since initiation of ustekinumab, she has been in clinical and biochemical remission from a CD and PV standpoint for the last 12 months.

## Lay Summary

Pyostomatitis vegetans (PV) is a rare inflammatory condition of the mouth/lips that is associated with inflammatory bowel diseases (IBD). Treating underlying IBD helps control PV. We present the first case of Crohn's disease-associated PV that was successfully treated with ustekinumab.

**Keywords:** Crohn's disease, Pyostomatitis vegetans, ustekinumab, inflammatory bowel diseases

## INTRODUCTION

Pyostomatitis vegetans (PV) is a rare inflammatory stomatitis that is often seen in association with inflammatory bowel diseases (IBD). It is more commonly seen in patients with ulcerative colitis (UC) compared with those with Crohn's disease (CD).<sup>1</sup> Amongst IBD patients, the intestinal symptoms often precede the oral PV by several months or years. The clinical course of PV usually parallels the activity of IBD. Treatment approach of PV depends on the presence of coexisting IBD. In patients with IBD, management of PV is often based on the therapy utilized to treat the underlying gastrointestinal disease.<sup>2-6</sup> There have been reports showing that the muco-cutaneous lesions regress following the management, whether medical or surgical, of the inflamed gastrointestinal

tract.<sup>4-6</sup> In the absence of IBD, topical steroids have been found to be efficacious in PV, but in many cases, there is a need for systemic therapy using systemic steroids, dapsone, sulfasalazine, azathioprine, and sulfamethoxypyridazine.<sup>2-6</sup> In certain cases, anti-tumor necrosis factor (anti-TNF) biologic therapy is needed to control the PV.<sup>7</sup>

Prior to this case, there have been no reports on the use of ustekinumab for the treatment of PV. There have been, however, case reports on the use of ustekinumab in patients with pyoderma gangrenosum (PG)<sup>8</sup> and uveitis.<sup>9</sup> Here we will discuss a case of PV treated successfully with ustekinumab.

## CASE REPORT

A 26-year-old female with mild psoriasis and long-standing CD presented to our clinic for further evaluation of recurrent lip and chin swelling as well as loose bowel movements and abdominal pain. Her history dates back to when she was 8 years old when she was diagnosed with CD in the setting of abdominal pain, diarrhea, and weight loss. Initially, she was placed on mesalamine (Asacol) and azathioprine which maintained her in remission for 8 years. She then self-discontinued the medications because she was feeling well. She remained on no CD treatment for the following 10 years. Overall, she remained well, but would experience episodes of abdominal pain and diarrhea two to three times a year with associated episodes of chin and lip swelling. She would get admitted to the hospital for a few days to receive intravenous steroids. She is currently on no medications.

Upon presentation to our clinic, she had severe lip and chin swelling with reddish blotches over her lower face and

Received for publications January 3, 2020; Editorial Decision February 18, 2020.

<sup>\*</sup>Division of Gastroenterology and Hepatology, American University of Beirut, Beirut, Lebanon; <sup>†</sup>Department of Internal Medicine, American University of Beirut, Beirut, Lebanon; <sup>‡</sup>Department of Dermatology, American University of Beirut, Beirut, Lebanon

Conflicts of interest: No conflicts of interest exist.

Funding: None reported.

Address correspondence to: Jana G. Hashash, MD, MSc, Division of Gastroenterology and Hepatology, American University of Beirut, Beirut, Lebanon (ja38@aub.edu.lb)

© 2020 Crohn's & Colitis Foundation. Published by Oxford University Press on behalf of Crohn's & Colitis Foundation.

This is an Open Access article distributed under the terms of the Creative Commons Attribution Non-Commercial License (<http://creativecommons.org/licenses/by-nc/4.0/>), which permits non-commercial re-use, distribution, and reproduction in any medium, provided the original work is properly cited. For commercial re-use, please contact [journals.permissions@oup.com](mailto:journals.permissions@oup.com)

doi: 10.1093/crocol/otaa014

Published online 13 March 2020

neck. She was unable to eat or drink because of excruciating lip pain. Additionally, she had lower abdominal pain and diarrhea.

Physical examination showed lip swelling, a red puffy chin as well as neck erythema (Fig. 1A and B). There were few erosions and small punctate pustules noted on her lips, hard palate, and buccal mucosa. Abdominal examination revealed right lower quadrant tenderness. Blood work showed a hemoglobin of 12.8 mg/dL, MCV 84 fl, 8,400/cu.mm white blood cells, 82% neutrophils, and a CRP of 49.1 mg/L (upper limit: 2.5 mg/L). Iron saturation was 6.2%. A glucose-6-P-dehydrogenase level was normal.

Colonoscopy showed a normal colon but a congested erythematous ileum with scattered ulcers (Fig. 1C and D). Upper endoscopy was normal. Biopsies from the ileum showed chronic active ileitis consistent with active CD. Magnetic resonance enterography (MRE) showed a long segment of diseased ileum (~20 cm) characterized by wall thickening, stratified enhancement, and luminal narrowing involving the most distal 5 cm, at the level of the terminal ileum, and diffuse mild wall thickening and hyper-enhancement of the remainder of the segment up to 20 cm proximal to the ileocecal valve (Fig. 1E and F).

The patient was referred to our dermatology colleagues for their input on the patient's lip/chin findings. The differential diagnosis included angioedema, cheilitis granulomatosa, and other autoimmune blistering disorders such as pemphigus.<sup>3, 10</sup> Clinically, the pustular, eroded, and/or crusty plaques of PV differ from the lip swelling and lack of superficial epithelial changes that are seen in angioedema (which is an episodic lip swelling that may or may not be associated with urticaria) or cheilitis granulomatosa (which is an asymptomatic lip swelling that is initially episodic but later becomes persistent). Autoimmune blistering disorders do not typically show a pustular component clinically. In case of doubt, a biopsy can help exclude cheilitis granulomatosa which typically shows epithelioid histiocytic granulomas, or autoimmune intraepidermal blistering disorders which typically show intraepidermal acantholysis with positive immunofluorescence testing.

After completing her gastrointestinal evaluation and after consulting with our dermatology colleagues, it was decided to start the patient on a short course of Prednisone which helped with her PV. Soon after the steroid taper was completed, her PV recurred. By that time, her pre-biological work-up was completed, and she was started on ustekinumab monotherapy. A few days after her IV Stelara infusion, her PV crusted (Fig. 1G) and disappeared, and her abdominal pain and diarrhea resolved. Since initiation of ustekinumab, her PV and her gastrointestinal symptoms have not recurred. The patient's CD has been in remission based on symptoms and noninvasive inflammatory markers for the past 12 months since starting the ustekinumab. Prior to this case, there have been no published reports on the use of ustekinumab for the treatment of PV.

## DISCUSSION

PV, first described in 1949, is a rare inflammatory stomatitis that is often seen in association with IBD.<sup>1</sup> PV is more common in males rather than females with a 3:1 ratio. It can occur at any age, but usually affects people in their mid-30s.<sup>1</sup>

PV oral lesions are benign. They consist of multiple small white and yellow pustules with an erythematous and edematous mucosal background. If these pustules rupture, they fuse and lead to a "snail-track" appearance. Those lesions can be painful or painless. On histology, we can see intra and sub epithelial micro abscesses with high number of eosinophils and neutrophils.<sup>2-6</sup>

The gastrointestinal symptoms usually precede oral PV by several months or years.<sup>1-4,6</sup> In patients with concomitant IBD, the clinical course of PV usually parallels the activity of IBD.<sup>3</sup> Some reports showed that following the management (medical or surgical) of UC, there was regression of the muco-cutaneous lesions. From the literature, there appears to be general consensus that the bowel should be explored in all patients with PV as this entity appears to be a specific marker for IBD.<sup>4</sup>

Treatment of PV depends on the presence of coexisting IBD. In patients with IBD, management of PV is often based on the therapy utilized to treat the underlying gastrointestinal disease.<sup>2-6</sup> In the absence of IBD, topical steroids are usually efficacious in PV, but in many cases, there will be a need for systemic therapy using systemic steroids, dapsone, sulfasalazine, azathioprine, and sulfamethoxypyridazine.<sup>2-6</sup> It was found that three injections of 5 mg/kg infliximab and successive maintenance therapy with 25 mg of methotrexate weekly (starting 7 days after the first infliximab induction dose) can cause a rapid and complete regression of both the PV and IBD.<sup>6,7</sup> Colectomy for severe cases of UC has resulted in permanent remission of PV.<sup>6</sup> The use of antimicrobials has been unhelpful, despite the pustular nature of the condition given the putative role of microorganisms in the pathogenesis.<sup>4</sup>

Prior to this case, there have been no published reports on the use of ustekinumab for the treatment of PV. Recently, however, there have been several case reports showing the success of ustekinumab use in patients with PG<sup>8</sup> and noninfectious uveitis.<sup>9</sup> There have been no studies evaluating the direct relationship between IL-23 and PV, but there is evidence looking at the role of IL-23 in patients with PG, a condition who many experts believe that PV is a subtype/oral counterpart of.<sup>11</sup> It has been proposed that refractory PG lesions may demonstrate increased interleukin-23 expression suggesting that ustekinumab may be used for inducing remission of refractory PG.<sup>8</sup> Similarly, it is suggested that interleukin-23 may have a crucial role in the pathogenesis of noninfectious uveitis as higher cytokine levels and single nucleotide polymorphisms in the IL-23 receptor gene were found to be associated with several inflammatory diseases complicated by noninfectious uveitis. Recent successful cases have been published on using ustekinumab for the treatment of noninfectious uveitis associated with CD.<sup>9</sup>

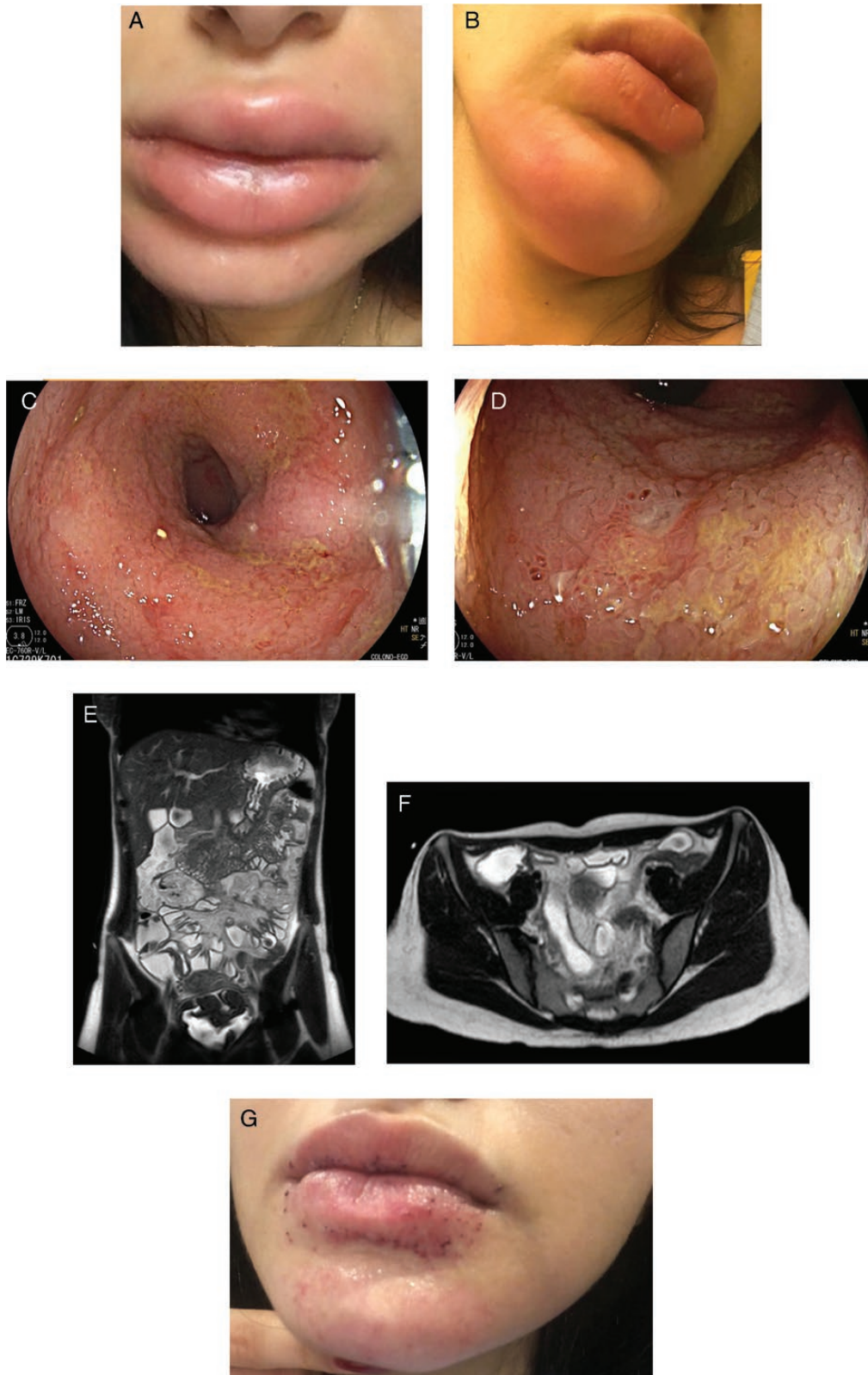


FIGURE 1. Photograph showing swelling of the patient's lips (A). Photograph showing pustules on the patient's lips as well as swelling and redness of her chin (B). Endoscopic appearance of the terminal ileum revealing congested mucosa, erythema and mild narrowing (C). Endoscopic appearance of a couple of ileal ulcers (D). Coronal cut of magnetic resonance imaging revealing small bowel Crohn's disease (E). Axial cut of magnetic resonance imaging revealing small bowel Crohn's disease (F). Photograph showing crusting over of the patient's pyostomatitis vegetans (G).

## CONCLUSION

PV is a rare inflammatory stomatitis and it is often seen in association with IBD. One treatment option that might be considered is ustekinumab, given its low immunogenicity and favorable safety profile.

## REFERENCES

1. Tan CX, Brand HS, de Boer NK, Forouzanfar T. Gastrointestinal diseases and their oro-dental manifestations: part 2: ulcerative colitis. *Br Dent J*. 2017;222:53–57.
2. Field EA, Allan RB. Review article: oral ulceration–aetiopathogenesis, clinical diagnosis and management in the gastrointestinal clinic. *Aliment Pharmacol Ther*. 2003;18:949–962.
3. Nico MM, Hussein TP, Aoki V, Lourenço SV. Pyostomatitis vegetans and its relation to inflammatory bowel disease, pyoderma gangrenosum, pyodermatitis vegetans, and pemphigus. *J Oral Pathol Med*. 2012;41:584–588.
4. Hegarty AM, Barrett AW, Scully C. Pyostomatitis vegetans. *Clin Exp Dermatol*. 2004;29:1–7.
5. Ruiz-Roca JA, Berini-Aytés L, Gay-Escoda C. Pyostomatitis vegetans. Report of two cases and review of the literature. *Oral Surg Oral Med Oral Pathol Oral Radiol Endod*. 2005;99:447–454.
6. Femiano F, Lanza A, Buonaiuto C, et al. Pyostomatitis vegetans: a review of the literature. *Med Oral Patol Oral Cir Bucal*. 2009;14:E114–E117.
7. Bens G, Laharie D, Beylot-Barry M, et al. Successful treatment with infliximab and methotrexate of pyostomatitis vegetans associated with Crohn's disease. *Br J Dermatol*. 2003;149:181–184.
8. Vallerand IA, Hardin J. Ustekinumab for the treatment of recalcitrant pyoderma gangrenosum: a case report. *SAGE Open Med Case Rep*. 2019;7:2050313X19845206.
9. Chateau T, Angioi K, Peyrin-Biroulet L. Two cases of successful ustekinumab treatment for non-infectious uveitis associated with Crohn's disease. *J Crohns Colitis*. 2019. doi: 10.1093/ecco-jcc/jjz167
10. Karouni M, Bergqvist C, Kurban M, Abbas O. Asymptomatic upper lip swelling in an 8-year-old boy. *Pediatr Dermatol*. 2017;34:479–480.
11. Guenova E, Teske A, Fehrenbacher B, et al. Interleukin 23 expression in pyoderma gangrenosum and targeted therapy with ustekinumab. *Arch Dermatol*. 2011;147:1203–1205.